










Colorectal polypectomy and endoscopic mucosal resection: European Society of Gastrointestinal Endoscopy (ESGE) Guideline – Update 2024



Authors

Monika Ferlitsch^{1,2}, Cesare Hassan^{3,4}, Raf Bisschops⁵ , Pradeep Bhandari⁶, Mário Dinis-Ribeiro^{7,8,9}, Mauro Risio¹⁰, Gregorios A. Paspatis¹¹, Alan Moss^{12,13}, Diogo Libânio^{7,8,9} , Vicente Lorenzo-Zúñiga^{14,15} , Andrei M. Voiosu^{16,17} , Matthew D. Rutter^{18,19} , Maria Pellisé^{20,21} , Leon M. G. Moons²², Andreas Probst²³, Halim Awadie²⁴ , Arnaldo Amato²⁵ , Yoji Takeuchi²⁶ , Alessandro Repici^{3,4}, Gabriel Rahmi^{27,28}, Hugo U. Koecklin^{29,30} , Eduardo Albéniz³¹ , Lisa-Maria Rockenbauer¹, Elisabeth Waldmann¹, Helmut Messmann²², Konstantinos Triantafyllou³² , Rodrigo Jover³³, Ian M. Gralnek^{24,34}, Evelien Dekker³⁵ , Michael J. Bourke^{36,37}

Institutions

- 1 Department of Internal Medicine III, Division of Gastroenterology and Hepatology, Medical University of Vienna, Vienna, Austria
- 2 Department of Gastroenterology, Evangelical Hospital, Vienna, Austria
- 3 Department of Biomedical Sciences, Humanitas University, Pieve Emanuele, Italy
- 4 Endoscopy Unit, Humanitas Clinical and Research Center – IRCCS, Rozzano, Italy
- 5 Department of Gastroenterology and Hepatology, University Hospitals Leuven, TARGID, KU Leuven, Leuven, Belgium
- 6 Endoscopy Department, Portsmouth Hospitals University NHS Trust, Portsmouth, UK
- 7 Department of Gastroenterology, Portuguese Oncology Institute of Porto, Porto, Portugal
- 8 MEDCIDS/Faculty of Medicine, University of Porto, Porto, Portugal
- 9 Porto Comprehensive Cancer Center (Porto.CCC) and RISE@CI-IPOP (Health Research Network), Porto, Portugal
- 10 Department of Pathology, Institute for Cancer Research and Treatment, Candiolo, Turin, Italy
- 11 Gastroenterology Department, Venizeleio General Hospital, Heraklion, Crete, Greece
- 12 Department of Gastroenterology, Western Health, Melbourne, Australia
- 13 Department of Medicine, Western Health, Melbourne Medical School, University of Melbourne, Melbourne, Australia
- 14 Endoscopy Unit, La Fe University and Polytechnic Hospital / IISLaFe, Valencia, Spain
- 15 Department of Medicine, Catholic University of Valencia, Valencia, Spain
- 16 Gastroenterology Department, Colentina Clinical Hospital, Bucharest, Romania
- 17 Internal Medicine and Gastroenterology, Carol Davila University of Medicine and Pharmacy, Bucharest, Romania
- 18 Department of Gastroenterology, North Tees and Hartlepool NHS Foundation Trust, Stockton-on-Tees, UK
- 19 Department of Gastroenterology, Faculty of Medical Sciences, Newcastle University, Newcastle-upon-Tyne, UK
- 20 Department of Gastroenterology, Hospital Clínic de Barcelona, Institut d'Investigacions Biomèdiques August Pi i Sunyer (IDIBAPS), Barcelona, Spain
- 21 Centro de Investigación Biomédica en Red de Enfermedades Hepáticas y Digestivas (CIBEREHD), University of Barcelona, Barcelona, Spain
- 22 III Medizinische Klinik, Universitätsklinikum Augsburg, Augsburg, Germany
- 23 Department of Gastroenterology, University Hospital of Augsburg, Augsburg, Germany
- 24 Ellen and Pinchas Mamber Institute of Gastroenterology and Hepatology, Emek Medical Center, Afula, Israel
- 25 Digestive Endoscopy and Gastroenterology Department, Ospedale A. Manzoni, Lecco, Italy
- 26 Department of Gastroenterology and Hepatology, Gunma University Graduate School of Medicine, Gunma, Japan
- 27 Hepatogastroenterology and Endoscopy Department, Hôpital européen Georges Pompidou, Paris, France

- 28 Laboratoire de Recherches Biochirurgicales, APHP-Centre Université de Paris, Paris, France
- 29 Hospital Universitari Germans Trias i Pujol, Badalona, Spain
- 30 Teknon Medical Center, Barcelona, Spain
- 31 Gastroenterology Department, Hospital Universitario de Navarra (HUN); Navarrabiomed, Universidad Pública de Navarra (UPNA), IdiSNA, Pamplona, Spain
- 32 Hepatogastroenterology Unit, Second Department of Propaedeutic Internal Medicine, Medical School, National and Kapodastrian University of Athens, Attikon University General Hospital, Athens, Greece
- 33 Servicio de Medicina Digestiva, Hospital General Universitario Dr. Balmis, Instituto de Investigación Sanitaria ISABIAL, Departamento de Medicina Clínica, Universidad Miguel Hernández, Alicante, Spain
- 34 Rappaport Faculty of Medicine Technion Israel Institute of Technology, Haifa, Israel
- 35 Department of Gastroenterology and Hepatology, Amsterdam University Medical Centers, Amsterdam, The Netherlands
- 36 Department of Gastroenterology and Hepatology, Westmead Hospital, Sydney, Australia
- 37 University of Sydney, Sydney, Australia

published online 26.4.2024

Bibliography

Endoscopy

DOI 10.1055/a-2304-3219


ISSN 0013-726X

© 2024. European Society of Gastrointestinal Endoscopy

All rights reserved.

This article is published by Thieme.

Georg Thieme Verlag KG, Rüdigerstraße 14,
70469 Stuttgart, Germany

 Supplementary Material
Supplementary Material is available under
<https://doi.org/10.1055/a-2304-3219>

Corresponding author

Monika Ferlitsch, MD, Division of Gastroenterology and Hepatology, Dept. of Internal Medicine III, Medical University of Vienna, Waehringer Guertel 18-20, A-1090 Vienna, Austria
monika.ferlitsch@meduniwien.ac.at

MAIN RECOMMENDATIONS

1 ESGE recommends cold snare polypectomy (CSP), to include a clear margin of normal tissue (1–2 mm) surrounding the polyp, for the removal of diminutive polyps (≤ 5 mm). Strong recommendation, high quality of evidence.

2 ESGE recommends against the use of cold biopsy forceps excision because of its high rate of incomplete resection. Strong recommendation, moderate quality of evidence.

3 ESGE recommends CSP, to include a clear margin of normal tissue (1–2 mm) surrounding the polyp, for the removal of small polyps (6–9 mm). Strong recommendation, high quality of evidence.

4 ESGE recommends hot snare polypectomy for the removal of nonpedunculated adenomatous polyps of 10–19 mm in size. Strong recommendation, high quality of evidence.

5 ESGE recommends conventional (diathermy-based) endoscopic mucosal resection (EMR) for large (≥ 20 mm) nonpedunculated adenomatous polyps (LNPCPs). Strong recommendation, high quality of evidence.

6 ESGE suggests that underwater EMR can be considered an alternative to conventional hot EMR for the treatment of adenomatous LNPCPs. Weak recommendation, moderate quality of evidence.

7 Endoscopic submucosal dissection (ESD) may also be suggested as an alternative for removal of LNPCPs of ≥ 20 mm in selected cases and in high-volume centers. Weak recommendation, low quality evidence.

8 ESGE recommends that, after piecemeal EMR of LNPCPs by hot snare, the resection margins should be treated by thermal ablation using snare-tip soft coagulation to prevent adenoma recurrence. Strong recommendation, high quality of evidence.

9 ESGE recommends (piecemeal) cold snare polypectomy or cold EMR for SSLs of all sizes without suspected dysplasia. Strong recommendation, moderate quality of evidence.

10 ESGE recommends prophylactic endoscopic clip closure of the mucosal defect after EMR of LNPCPs in the right colon to reduce the risk of delayed bleeding. Strong recommendation, high quality of evidence.

11 ESGE recommends that en bloc resection techniques, such as en bloc EMR, ESD, endoscopic intermuscular dissection, endoscopic full-thickness resection, or surgery should be the techniques of choice in cases with suspected superficial invasive carcinoma, which otherwise cannot be removed en bloc by standard polypectomy or EMR. Strong recommendation, moderate quality of evidence.

ABBREVIATIONS

AE	adverse event	LSL	laterally spreading lesion
AI	artificial intelligence	NBI	narrow-band imaging
CAST	cold-forceps avulsion with adjuvant snare-tip soft coagulation	NICE	NBI International Colorectal Endoscopic classification
CEMR	conventional endoscopic mucosal resection	OR	odds ratio
CRC	colorectal cancer	pCSP	piecemeal cold snare polypectomy
CSP	cold snare polypectomy	PPB	post-procedural bleeding
DMI	deep mural injury	RCT	randomized controlled trial
EFTR	endoscopic full-thickness resection	RR	risk ratio
EMR	endoscopic mucosal resection	SMI	submucosal invasion
ESD	endoscopic submucosal dissection	SMIC	submucosal invasive cancer
ESGE	European Society of Gastrointestinal Endoscopy	SSL	sessile serrated lesion
HGD	high grade dysplasia	STSC	snare-tip soft coagulation
HPP	hyperplastic polyp	TTS	through the scope
HSP	hot snare polypectomy	UEMR	underwater EMR
IPB	intraprocedural bleeding	VCE	virtual chromoendoscopy
IRR	incomplete resection rate	WASP	Workgroup serrated polyps and Polyposis
JNET	Japan NBI Expert Team	WLE	white-light endoscopy
LNPCP	large (≥ 20 mm) nonpedunculated colorectal polyp		

WHAT IS NEW?

- Cold snare polypectomy for all SSLs without dysplasia
- Thermal ablation of the margin after piecemeal EMR of LNPCPs
- Prophylactic endoscopic clip closure of the mucosal defect after EMR of LNPCPs in the right colon
- Underwater EMR as an alternative to conventional hot EMR for the treatment of adenomatous LNPCPs
- En bloc resection techniques, such as en bloc EMR, ESD, endoscopic intermuscular dissection, EFTR, or surgery should be the techniques of choice when superficial invasive carcinoma is suspected

An algorithm of the updated ESGE recommendations for the management of colorectal polyps is shown in ► **Fig. 1**.

SCOPE AND PURPOSE

This Guideline is an official statement of the European Society of Gastrointestinal Endoscopy (ESGE). The Grading of Recommendations Assessment, Development and Evaluation (GRADE) system was adopted to define the strength of recommendations and the quality of evidence.

1 Introduction

Endoscopic removal of colorectal polyps reduces the incidence and mortality of colorectal cancer (CRC) and is considered an essential skill for all endoscopists who perform colonoscopy

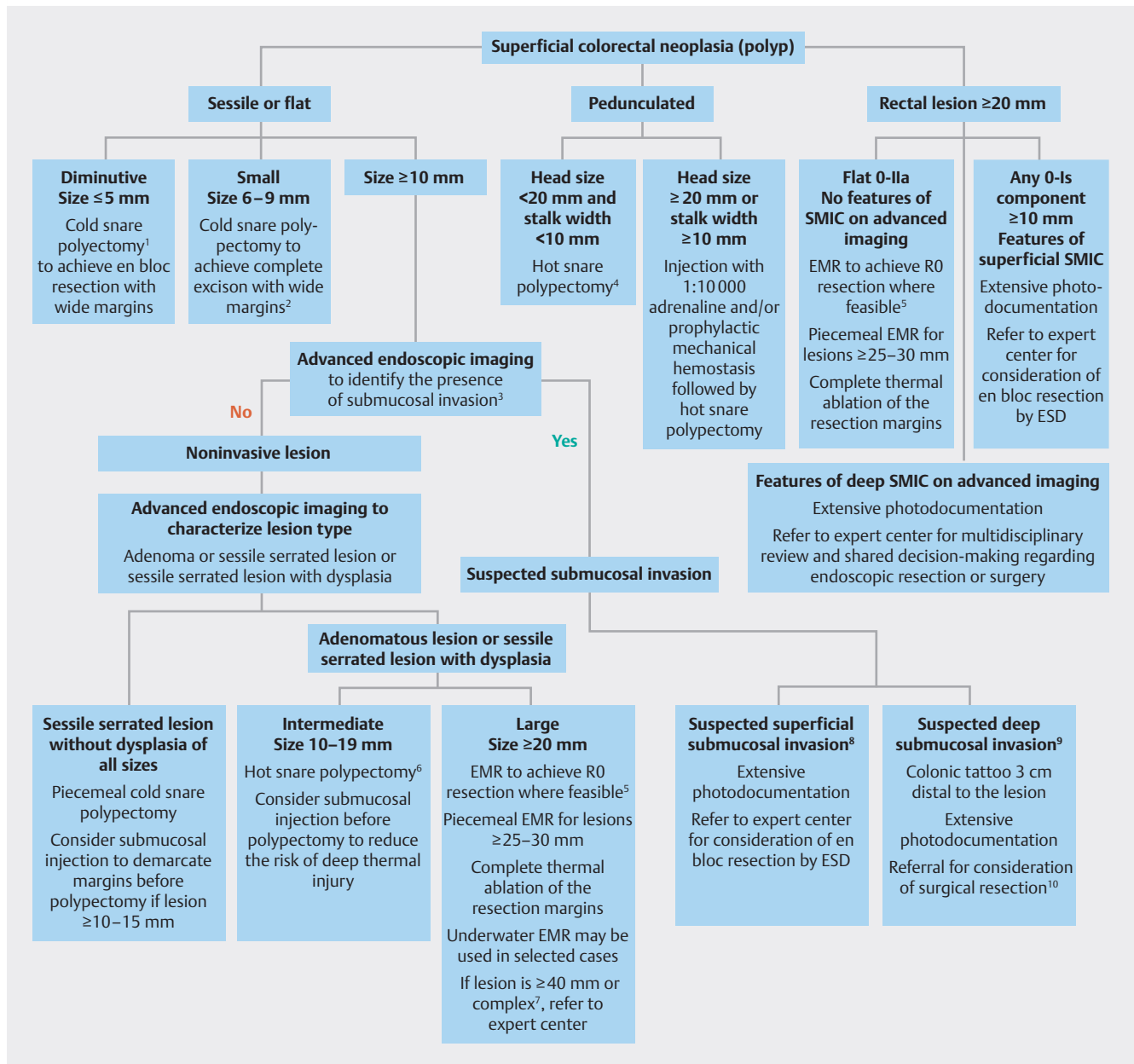
[1, 2]. Various polypectomy techniques and devices are available, with their use often varying on the basis of local preferences and availability [3–5]. This Guideline is an update of the 2017 European Society of Gastrointestinal Endoscopy (ESGE) colorectal polypectomy guideline [2]. It uses an evidence-based approach to address the major issues pertaining to the endoscopic removal of colorectal lesions, the cornerstone in CRC prevention.

This Guideline does not address the management of anti-coagulants and other medications in the periprocedural setting, nor post-polypectomy surveillance, as these are addressed in separate guidelines [6, 7].

2 Methods

The ESGE commissioned this Guideline and appointed a guideline leader (M.F.) who invited the listed authors to participate in the project development. The key questions were prepared by the coordinating team (M.F., C.H., M.J.B.) and then approved by the other members. The coordinating team formed task force subgroups, each with its own leader, and divided the key topics (polyp classification, polypectomy for polyps sized < 20 mm, endoscopic mucosal resection [EMR] for polyps ≥ 20 mm, technical considerations, adverse events [AEs], histopathology) among these task forces (**Appendix 1 s**, see online-only Supplementary material).

Each task force performed a systematic literature search to prepare evidence-based and well-balanced statements on their assigned key questions. Searches were performed in Medline/PubMed. Articles were first screened by their title; their relevance was then confirmed by review of the corresponding manuscript, and articles with content that was considered irrelevant were excluded. Evidence tables were generated for



► **Fig. 1** ESGE recommendations for the management of colorectal polyps. SMIC, submucosal invasive cancer; EMR, endoscopic mucosal resection; ESD, endoscopic submucosal dissection.

¹ Cold biopsy forceps can be considered as a second-line option, but should only be used for polyps sized ≤3 mm, where cold snare polypectomy is technically difficult.

² When en bloc resection is not achieved, oligo-piecemeal excision is appropriate, wide margins of normal tissue are necessary to ensure complete excision.

³ Standard chromoendoscopy if advanced endoscopic imaging is not available.

⁴ When bleeding risk is high owing to antiplatelet or anticoagulant medication or coagulopathy, an individualized approach is justified and prophylactic mechanical hemostasis should be considered.

⁵ This may be feasible for lesions of ≤25 mm and especially those in the left colon or rectum.

⁶ Piecemeal cold snare resection may be considered where the risk of deep thermal injury is high or cannot be tolerated, but further evidence of efficacy is required.

⁷ Difficult location or poor access (e.g. ileocecal valve, peri-appendiceal, or anorectal junction), prior failed attempts at resection, nonlifting with submucosal injection, SMSA 4.

⁸ Kudo Vi, JNET 2b, Sano IIIa.

⁹ Kudo Vn, JNET3, Sano IIIb, NICE 3, polyp morphology including ulceration, excavation, or deep demarcated depression.

¹⁰ Surgical resection is required because both the lesion and the local draining lymph nodes require excision.

each key question, summarizing the evidence of the available studies. For substantial outcomes, articles were individually assessed by the level of evidence and strength of recommendation according to the validated Grading of Recommendations Assessment, Development and Evaluation (GRADE) system [8,9].

Each task force proposed statements on their assigned key questions, which were discussed and voted on during a guideline meeting in Prague in April 2022. In July 2022, a draft prepared by the taskforce leaders and coordinating team was sent to all group members. The manuscript was also reviewed by two members of the ESGE Governing Board and sent for further comments to the National Societies and Individual Members. After agreement on a final version, the manuscript was submitted to the journal *Endoscopy* for publication. All authors agreed on the final revised manuscript.

This Guideline update was issued in 2024 and will be considered for review and update in 2029, or sooner if new and relevant evidence becomes available. Any updates to the Guideline in the interim will be noted on the ESGE website: <http://www.esge.com/esge-guidelines.html>.

3 Definition and classification of polyps

RECOMMENDATION

ESGE recommends that polyps should be described and reported according to their location, size (in millimeters), and morphology (Paris classification). Nonpolypoid lesions ≥ 10 mm (laterally spreading lesions) should also be classified as: (a) granular homogeneous; (b) granular nodular-mixed; (c) nongranular elevated; (d) nongranular pseudodepressed.

Strong recommendation, moderate quality of evidence.

RECOMMENDATION

ESGE recommends the performance and reporting of optical diagnosis, including polyp pit and vascular patterns, as recommended by the ESGE curriculum. This should be integrated with the macroscopic features and location to predict the risk of submucosal invasion.

Strong recommendation, moderate quality of evidence.

Superficial colorectal lesions are neoplastic or non-neoplastic epithelial lesions (serrated lesions including hyperplastic polyps [HPPs], or adenomas and adenocarcinomas) with their invasion depth limited to the epithelium, mucosa, or submucosa. Morphology, size, location, and mucosal/vascular pattern are features associated with the risk of submucosal invasion (SMI) and their adequate characterization is important in the choice of resection technique.

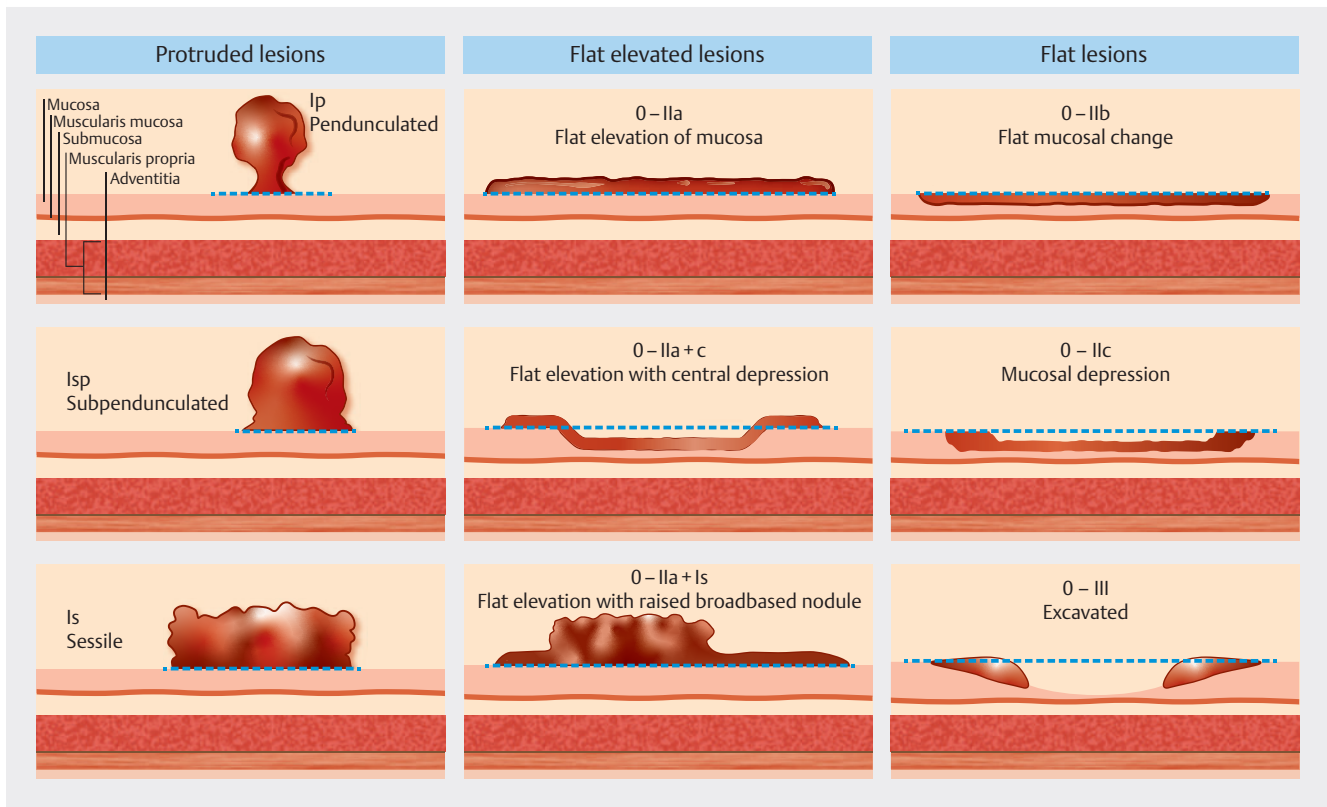
The morphology of colorectal lesions should be classified according to the Paris classification (► Fig. 2) [5]. Sessile and in particular depressed lesions are associated with higher risks of

advanced histology and SMI when compared with 0-IIa lesions [3,4]; however, interobserver agreement using the Paris classification is only moderate ($k=0.42$) [5], and it has been suggested that a simplified classification with three categories (pedunculated, elevated [sessile/flat], and depressed) outperforms the Paris classification [6].

Sessile and flat adenomatous lesions ≥ 10 mm should also be classified as granular (homogeneous or nodular-mixed) or non-granular (elevated or pseudodepressed) as these different types are associated with different risks of submucosal invasive cancer (SMIC). A meta-analysis found that the risk of SMIC is higher in the nongranular pseudodepressed subtype (31.6%, 95%CI 19.8%–43.4%), followed by granular nodular-mixed (10.5%, 95%CI 5.9%–15.1%), nongranular flat-elevated (4.9% 95%CI 2.1%–7.8%) and granular-homogeneous types (0.5%, 95%CI 0.1%–1.0%) [7]. Rectosigmoid location and greater lesion size are also associated with a higher risk of SMIC [4,7,8].

Dye-based and/or virtual chromoendoscopy (VCE) are also important for the prediction of histology and invasion depth. A prospective comparative study of 400 lesions, mean size 35 mm, revealed that dye-based chromoendoscopy offers no additional benefit over the use of VCE when evaluating for a demarcated area of altered pit or microvascular pattern [10]. The finding of a demarcated area with VCE was 91% (95%CI 87.7%–93.5%) accurate for SMI on final histology. Interobserver agreement was very high ($k=0.96$). Starting the evaluation of a demarcated area with VCE is an important initial imaging technique in lesion assessment and warrants further systematic study [10]. In general, flat noninvasive lesions have a homogeneous surface pattern. A detailed knowledge of the classification systems is not necessary to perform this evaluation, which may be useful for the nonexpert.

The most used classifications for the prediction of histology and SMI are the Kudo pit pattern, Narrow-band imaging (NBI) International Colorectal Endoscopic (NICE) classification, and Japan NBI Expert Team (JNET) classification (► Fig. 3). For optical diagnosis of serrated polyps and conventional adenomas < 10 mm, the Workgroup serrated polyps and Polyposis (WASP) classification system can be used. The WASP classification (► Fig. 4) is a stepwise approach based on the NICE classification using high resolution white-light endoscopy (WLE) and NBI. As the first step, the classification distinguishes between type 1 polyps (HPPs or serrated lesions) and type 2 polyps (serrated lesions or conventional adenomas). Diagnosis of a type 2 polyp requires two of the following features: (i) darker color than the surrounding mucosa; (ii) prominent brown vessels; or (iii) an oval, tubular, or branched surface pattern. To distinguish between serrated lesions and HPPs for type 1 polyps and between serrated lesions and conventional adenomas for type 2 polyps, at least two of the following features must be present: (i) a crowded surface; (ii) indistinct borders; (iii) irregular shape; (iv) space between dark spots inside the crypt [11,12]. A detailed review of these classifications and their performance can be found within the dedicated ESGE guideline and curriculum for training and maintenance of competence in optical diagnosis [9,13].



► Fig. 2 Schematic illustrating the original Paris classification of superficial neoplastic lesions [5].

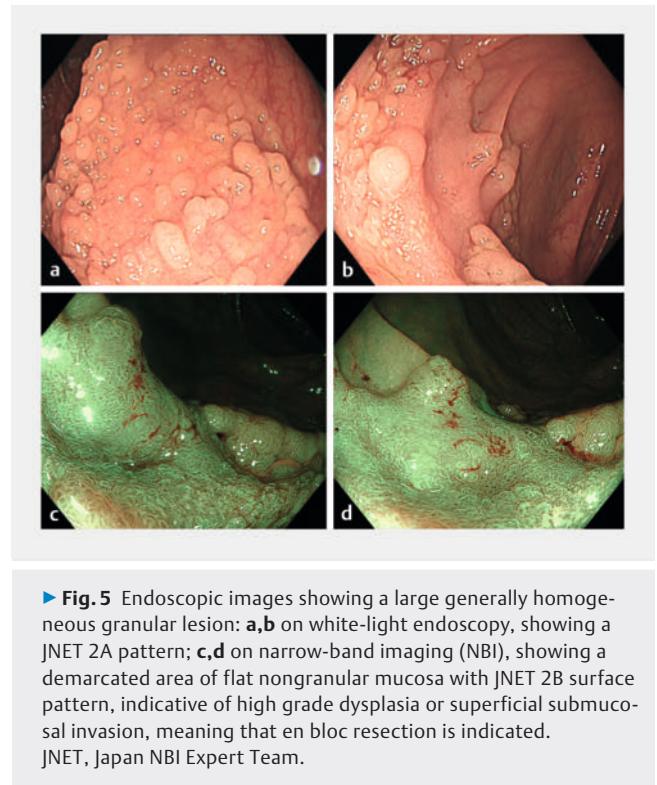
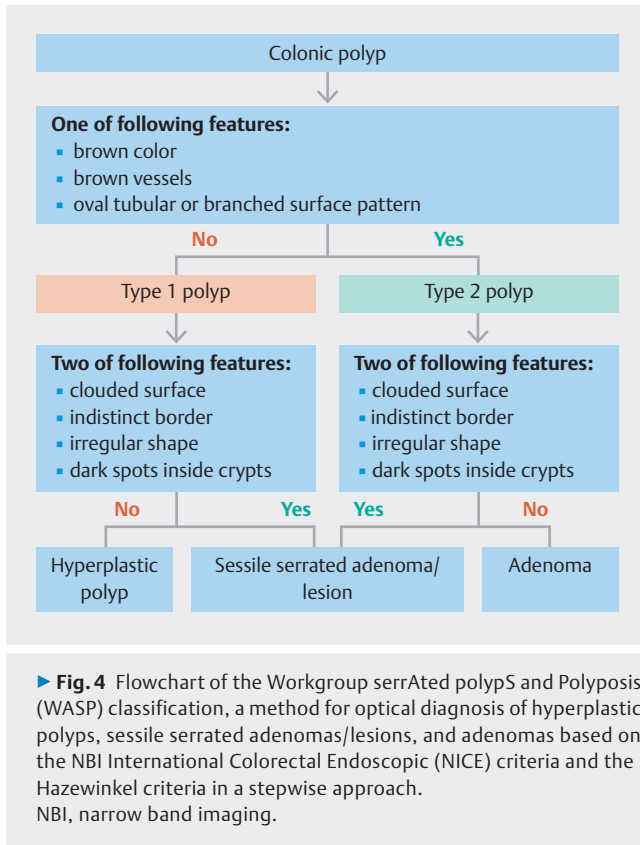
NBI	Type 1	Type 2A	Type 2B	Type 3
Vessel pattern	Invisible*	Regular caliber; regular distribution (meshed/spiral pattern)**	Irregular distribution	Loose vessel areas; interruption of thick vessels
Surface pattern	Regular dark or white spots; similar to surrounding normal mucosa	Regular (tubular/branched/papillary)	Irregular or obscure	Amorphous areas
Most likely histology	Hyperplastic polyp/sessile serrated lesion	Low grade intramucosal neoplasia	High grade intramucosal neoplasia/superficial submucosal invasive cancer***	Deep submucosal invasive cancer
Example image				

* If visible, the caliber in the lesion is similar to the surrounding normal mucosa.

** Microvessels are often distributed in a punctate pattern and well-ordered reticular or spiral vessels may not be observed in depressed lesions.

*** Deep submucosal invasive cancer may be included.

► Fig. 3 The Japan NBI Expert Team (JNET) classification.



3.1 Identification of submucosal invasion

RECOMMENDATION

ESGE recommends the use of high definition white-light endoscopy in combination with virtual chromoendoscopy to detect the presence and predict the depth of submucosal invasion in large (≥ 20 mm) nonpedunculated colorectal polyps (LNPCPs) prior to selection of a treatment strategy.

Strong recommendation, high quality of evidence.

RECOMMENDATION

ESGE recommends that polyps with endoscopic imaging characteristics of deep submucosal invasion should be discussed by the multidisciplinary team before treatment.

Strong recommendation, moderate quality of evidence.

We refer here to the most recent guideline on “Advanced imaging for detection and differentiation of colorectal neoplasia” published in 2019 [9]. The statements mentioned there also apply to this guideline.

The pre-intervention estimation of the risk of SMI is crucial in choosing the ideal resection method and deciding if en bloc resection is needed. Lesion evaluation is divided into overview

and focal interrogation phases [9, 14]. Features such as ulceration, excavation, deep demarcated depression, Paris classification 0-IIc and 0-IIa+IIc, mucosal friability, fold convergence, and Kudo pit pattern V are associated with deep SMIC [4, 9, 14, 15]. Apart from pit pattern, these features should be visible with standard WLE in the overview phase. When a demarcated area, nodule, or depressed area is identified in the overview, these areas are interrogated with advanced imaging techniques using VCE. This approach improves the identification of the surface features associated with SMI, such as irregular or absent surface and vascular patterns [9, 14]. Sano capillary pattern IIB, Hiroshima C3, NICE 3, and JNET 3 are highly indicative of deep invasion [9, 14]. Kudo pit pattern Vn is associated with a high likelihood of deep SMI. Sano IIIA and Kudo pit pattern Vi are predictive of superficial SMIC and therefore may indicate lesions that are suitable for endoscopic cure by en bloc resection. Similarly, the JNET 2B pattern is indicative of at least high grade dysplasia (HGD) and often superficial SMIC and such lesions should undergo endoscopic en bloc resection [9, 14]. Benign lesions have surface homogeneity. When there is a disruption to this pattern, it may be possible to discern a demarcated area of altered pit and microvascular patterns. Such findings are indicative of SMIC and en bloc resection is indicated (► **Fig. 5**).

Using this simple approach that is available to all endoscopists, the sensitivity and specificity of the detection of SMIC in flat lesions were shown, in a large prospective cohort study of 1500 large nonpedunculated colorectal polyps (LNPCPs), to be 91% and 96%, respectively [7]. This is termed “overt SMIC.” Conversely, the detection of SMIC in bulky LNPCPs does not enjoy this level of accuracy as the focus of cancer may be hidden

within the lesion and not expressed on the surface. This is termed “covert SMIC.” In this situation, the risk of SMIC is determined by lesion morphology, surface granularity, location in the colon, and size, with lesions ≥ 40 mm having a greater risk [4, 8]. The risk is greater in larger lesions in the distal colon and rectum. For such lesions, consideration of en bloc resection is appropriate, particularly for lesions in the rectum, where a selective resection algorithm has been proven to be very successful, achieving endoscopic cure by endoscopic submucosal dissection (ESD) in all eligible LNPCPs [16].

3.2 Determination of the most advanced pathology

RECOMMENDATION

ESGE recommends the use of high quality photo- and/or videodocumentation in preference to biopsies to determine the most advanced pathology in LNPCPs and to inform selection of the optimal treatment strategy or facilitate tertiary referral. Where deep submucosal invasion is suspected, biopsies are indicated. Strong recommendation, high quality of evidence.

Endoscopic biopsy is not an accurate means of sampling an LNPCP. In a large series of 586 LNPCPs undergoing pre-resection biopsy, the sensitivity for HGD was only 21% (95%CI 11.5%–35.1%) [17]. Where the EMR specimen showed HGD, the pre-resection biopsy detected low grade dysplasia (LGD) in 77% of cases. The role of endoscopic biopsy should generally be limited to when deep SMIC is suspected. Further, biopsies can cause fibrosis, making polypectomy, EMR, or ESD more difficult or impossible.

High quality video- and still photodocumentation of lesions that are not amenable to treatment by the primary endoscopist can facilitate referrals and further therapeutic planning. This process includes cleaning of the lesion and visualization of all parts in high definition WLE and VCE, including with magnification if available, particularly for depressed areas or dominant nodules – commonly at least 8–10 different images are appropriate. Based on this documentation, the referral center can assess whether an attempt at endoscopic treatment is justified, allocate appropriate time, and avoid unnecessary additional diagnostic procedures.

When deep SMI is suspected, biopsies need to be taken from the depressed, demarcated area, or the area of most disordered pit/vascular pattern to increase the yield of forceps biopsy in deep SMIC.

4 Removal and retrieval of polyps for histology

RECOMMENDATION

ESGE recommends resection of all polyps with the exception of diminutive (≤ 5 mm) rectosigmoid polyps that are predicted to be nonadenomatous with high confidence. Strong recommendation, high quality of evidence.

Most colorectal polyps are diminutive (≤ 5 mm), and advanced histology/cancer is very rare in these lesions (0–0.5%). HPPs located in the rectosigmoid have an even lower risk of advanced histology and a negligible risk of progression, therefore a “diagnose and leave behind” strategy is appropriate to reduce polypectomy risks, pathology workload, and costs. According to the recently published ESGE Simple Optical Diagnosis Accuracy (SODA) criteria, the sensitivity and specificity to implement this strategy for adenomatous histology should be $\geq 90\%$ and $\geq 80\%$, respectively [18], as confirmed by an ASGE meta-analysis [19]. Artificial intelligence (AI) characterization systems have also shown promising results in achieving the negative predictive value (NPV) threshold and can be used to aid in the diagnosis of diminutive rectosigmoid polyps [20].

RECOMMENDATION

ESGE recommends retrieval and histopathologic analysis of resected polyps. A resect-and-discard strategy using real-time optical diagnosis with virtual or dye-based chromoendoscopy for diminutive colorectal polyps should be reserved for experts only. Strong recommendation, high quality of evidence.

Given the low likelihood of advanced histology or cancer in diminutive polyps, the “resect and discard” strategy could be applied if optical diagnosis can be demonstrated to have a $\geq 90\%$ agreement in the assignment of post-polypectomy surveillance intervals compared with those based on histopathologic analysis. A meta-analysis published in 2015 showed that the agreement in assignment of post-polypectomy surveillance intervals with NBI was 89% (95%CI 85%–93%), with surveillance agreements $>90\%$ only for academic medical centers, expert users, and when the prediction was made with high confidence [19]. Two AI studies showed promising results in polyp characterization and AI may be helpful in achieving the required thresholds in the future [18, 20].

► **Table 1** Differences in the methods for removal of colorectal polyps.

Removal method	Size, mm	Injection	Current use	En bloc	Piecemeal
Polypectomy	<20	No	Hot or cold	Yes	Yes
Lift polypectomy	<20	Yes	Hot or cold	Yes	Yes
EMR	≥20	Yes	Hot or cold	Yes	Yes
Underwater EMR	≥20	No	Hot or cold	Yes	Yes

EMR, endoscopic mucosal resection.

5 Definitions of polypectomy and mucosectomy

Colonic polypectomy is the removal of colorectal polyps (► **Table 1**). Usually, lesions <20 mm should be removed during the index procedure. Depending on the polyp size and morphology, nonelectrocautery-assisted “cold” or electrocautery-assisted “hot” snare polypectomy can be used. Polypectomy is generally used for polyps ≤19 mm. When submucosal injection is used, the polypectomy is called a “lift polypectomy.” EMR is reserved for the removal of polyps ≥20 mm and involves the injection of different solutions into the submucosal space, followed by cold or hot snare resection of the lesion. EMR can be done en bloc or piecemeal according to the size, shape, and location of the lesion. Underwater EMR (UEMR) is performed in a water-distended colon with gas exclusion [14, 21, 22].

RECOMMENDATION

ESGE recommends that the majority of colonic and rectal lesions can be effectively removed in a curative way by standard polypectomy and/or by EMR.

Strong recommendation, high quality of evidence.

Snare polypectomy or EMR are effective for removing the majority of nonmalignant colonic polyps [23]. Piecemeal EMR for large polyps is associated with acceptable rates of residual/recurrent adenoma (16% in a large prospective study [24] and 15% in a meta-analysis [25]). This can be dramatically reduced to 1%–5% with thermal ablation of the post-EMR margin [26, 27]. Residual/recurrent lesions are usually diminutive in size and can mostly be removed endoscopically at surveillance colonoscopy, with a high success rate of 93% [24].

The EMR approach is safe, efficient, and cost-effective compared with surgical alternatives [28, 29]. The indications for EMR and ESD for colorectal lesions were addressed in the recent ESD guideline [30] and apply also to this guideline. In particular, the current guideline takes into account the emerging role of ESD in achieving pathologic cure for rectal lesions, owing to the risk of covert invasive cancer in large nodular lesions.

6 Polypectomy of pedunculated polyps

RECOMMENDATION

ESGE recommends hot snare polypectomy for pedunculated polyps.

Strong recommendation, high quality of evidence.

ESGE suggests the use of dilute adrenaline injection and/or mechanical hemostasis in pedunculated colorectal polyps with a head size of ≥2 cm or a stalk width of ≥1 cm to prevent immediate post-polypectomy bleeding.

Weak recommendation, low quality of evidence.

Most pedunculated polyps are readily removed completely by hot snare polypectomy (HSP); however, post-procedural bleeding (PPB) remains a risk, especially for those lesions with large heads or stalks. The size of the polyp has repeatedly been reported to be a major risk factor for PPB [31], with polyps >10 mm carrying a 4.5-fold greater risk than smaller ones. In a prospective study of 5152 patients with colorectal polyps [32], polyp-based multivariate analysis revealed that the risk factors for immediate PPB included older patient age (≥65 years); comorbid cardiovascular or chronic renal disease; anticoagulant use; polyp size >1 cm; gross morphology of the polyp, such as a pedunculated polyp or laterally spreading lesion (LSL); poor bowel preparation; cutting mode of the electrosurgical current; and the inadvertent cutting of a polyp before current application. In a retrospective multicenter study, 1147 pedunculated polyps were reviewed [31]. A stalk width of ≥6 mm was associated with immediate PPB (odds ratio [OR] 1.9, 95%CI 1.1–3.4). In addition, a protective effect of endoloop placement was shown in terms of immediate PPB for polyps >15 mm. With regard to delayed PPB, prophylactic clipping before polypectomy (OR 4.2, 95%CI 1.3–13) and injecting the stalk (OR 4.0, 95%CI 1.4–12) were paradoxically risk factors for delayed PPB [33, 34]. Recommendations for the prophylaxis of immediate PPB after polypectomy of large pedunculated polyps remain unchanged from the 2017 guideline [2].

Two retrospective studies [35, 36] and one prospective study [37] have shown that pedunculated polyps <1 cm that have thin stalks can safely be removed with the cold snare technique [38]. Where malignancy of a pedunculated polyp is suspected,

a tattoo should be placed prior to resection and the resection should be performed as close as possible to the base of the stalk.

7 Resection of flat and sessile lesions

7.1 Resection of diminutive polyps (≤ 5 mm)

RECOMMENDATION

ESGE recommends cold snare polypectomy for the removal of diminutive polyps (≤ 5 mm).

Strong recommendation, high quality of evidence.

ESGE recommends including a clear margin of normal tissue (1–2 mm) surrounding the polyp.

Strong recommendation, high quality of evidence.

RECOMMENDATION

ESGE recommends against the use of cold biopsy forceps excision because of its high rate of incomplete resection.

Strong recommendation, moderate quality of evidence.

RECOMMENDATION

ESGE recommends against the use of hot biopsy forceps because of its high rates of incomplete resection, inadequate tissue sampling for histopathologic examination, and the unacceptably high risk of adverse events (deep thermal injury and delayed bleeding) in comparison with cold snare excision.

Strong recommendation, high quality of evidence.

Since the publication of the last guideline, 10 new studies addressing the issue of cold snare polypectomy (CSP) versus biopsy forceps resection of small polyps and the safety of CSP versus HSP have become available. Most new studies have assessed the use of jumbo biopsy forceps in comparison to CSP. A meta-analysis by Srinivasan et al. [39] showed that the incomplete resection rate (IRR) for jumbo biopsy forceps was arithmetically higher compared with CSP, but this did not reach statistical significance. This meta-analysis was most likely underpowered and only included four studies, with one of these constituting $>50\%$ of the total of 407 patients.

CSP for polyps ≤ 3 mm remains the standard of care. This is underpinned by several prospective randomized controlled trials (RCTs). The first RCT showed an overall resection rate of 92.1%, with no difference between CSP and jumbo forceps, in 169 patients with 196 polyps of ≤ 5 mm [40]. Similarly, Desai et al. showed, for polyps ≤ 6 mm, an IRR of 11.1% for jumbo forceps biopsy and 7.7% for CSP ($P=0.41$) [41]. A multicenter noninferiority RCT in 123 patients with polyps ≤ 4 mm showed a significantly higher en bloc resection rate for CSP, but histologically there was no difference between CSP and biopsy forceps, which was confirmed by additional biopsies from the re-

section margin [42]. Similarly, for polyps ≤ 3 mm, a recent RCT showed a comparable 98.3% complete resection rate for both techniques [43]. A large observational study in 471 patients confirmed the safety and efficacy of jumbo biopsy forceps polypectomy, with a 99.4% complete resection rate. A multivariate analysis showed however that, if the technique was used for polyps >3 mm, there was a significantly higher risk of local recurrence after 1 year (OR 3.4; $P=0.02$) [44]. In line with this, Yamasaki et al. [45] reported that for polyps of 3, 4 and, 5 mm, a “one bite” approach was sufficient in 92%, 60%, and 31% of cases, respectively. Also, in comparison to hot biopsy forceps for polyps of 3–5 mm, the en bloc and complete resection rates were significantly higher for CSP. Taking these recent studies into consideration, ESGE recommends CSP as the standard technique.

7.2 Resection of small polyps (6–9 mm)

RECOMMENDATION

ESGE recommends cold snare polypectomy for the removal of small polyps (6–9 mm).

Strong recommendation, high quality of evidence.


ESGE recommends including a clear margin of normal tissue (1–2 mm) surrounding the polyp.

Strong recommendation, high quality of evidence.


A meta-analysis including 3195 polyps in 1665 patients from eight RCTs comparing HSP and CSP for polyps up to 10 mm in size found similar rates of complete resection (risk ratio [RR] 1.02, 95%CI 0.98–1.07; $P=0.31$) and polyp retrieval (RR 1.00, 95%CI 1.00–1.01; $P=0.60$) [46]. However, it also identified a non-significantly higher delayed bleeding rate after HSP on the basis of both patient (RR 7.53, 95%CI 0.94–60.24; $P=0.06$) and polyp analysis (RR 7.35, 95%CI 0.91–59.33; $P=0.06$), along with significantly longer times for total colonoscopy (mean difference 7.13 minutes, 95%CI 5.32–8.94; $P<0.001$) and polypectomy for HSP (mean difference 30.92 seconds, 95%CI 9.15–52.68; $P=0.005$). Other RCTs not included in the meta-analysis have corroborated these results [47–53]. In terms of AEs, in addition to the results from the RCTs, which were not powered to obtain high quality data on AEs, a retrospective Japanese study including 12 928 CSPs and 2408 HSPs for lesions of <10 mm (total of 5371 patients) demonstrated that the prevalence of PPB after HSP was higher than that after CSP (OR 6.0, 95%CI 1.34–26.8), even after propensity score matching [54] (► Fig. 6).

In a recent international multicenter parallel-design randomized trial of 660 patients, involving 17 endoscopists of varying experience, all of whom completed a CSP training module [9, 29], the use of a thin-wire (0.30 mm) or conventional thick-wire (0.47 mm) snare for CSP of small colorectal polyps (≤ 10 mm) resulted in a very low overall IRR of 1.5% (as proven by quadrantic resection margin biopsies) [55]. There was no difference in the IRRs in the thin- and thick-wire arms (RR

Cold snare polypectomy



Hot snare polypectomy



► **Fig. 6** Schematic showing the differences in technique for cold snare polypectomy and hot snare polypectomy. *Note: a margin of 1–2 mm of normal tissue should be included with the polyp. Image credit: Lisa-Maria Rockenbauer.

0.41, 95%CI 0.11–1.56; $P=0.21$) and no difference in AEs. The implication of this large multioperator RCT is that, irrespective of the snare wire diameter, optimal CSP technique is the primary determinant for achieving negligible IRRs.

7.3 Resection of flat and sessile polyps (10–19 mm)

RECOMMENDATION

ESGE recommends hot snare polypectomy (HSP) as the accepted standard of care for the removal of nonpedunculated adenomatous polyps of 10–19 mm in size. Strong recommendation, high quality of evidence.

ESGE suggests submucosal injection prior to HSP to reduce the risk of deep thermal mural injury. Weak recommendation, low quality of evidence.

RECOMMENDATION

ESGE recommends piecemeal cold snare polypectomy (pCSP) for sessile serrated lesions (SSLs) without dysplasia of 10–19 mm in size. Strong recommendation, high quality of evidence.

ESGE suggests submucosal injection may be used prior to pCSP to facilitate tissue transection and better delineate the polyp margins. Weak recommendation, low quality of evidence.

RECOMMENDATION

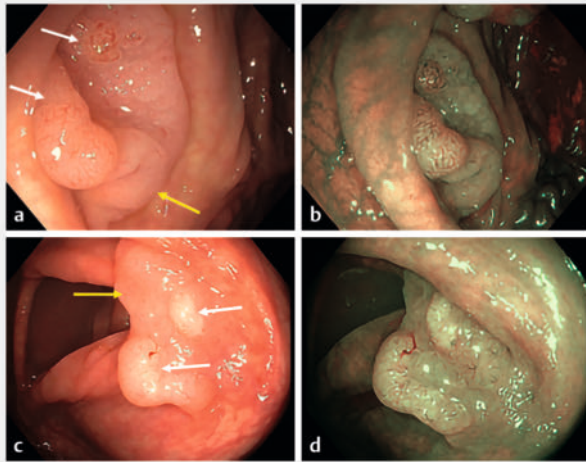
ESGE recommends hot snare polypectomy for the removal of SSLs with dysplasia and en bloc excision of the dysplastic component. Weak recommendation, low quality of evidence.

RECOMMENDATION

ESGE suggests consideration of piecemeal cold snare EMR for carefully selected flat adenomas of 10–19 mm (granular homogeneous LNPCPs), particularly in the right colon and especially when co-morbidity levels are high, to reduce the risks of deep mural injury and delayed post-EMR bleeding. Weak recommendation, low quality of evidence.

7.3.1 Hot snare polypectomy for polyps of 10–19 mm

HSP was historically preferred for polyps of 10–19 mm. HSP can achieve en bloc resection for polyps of this size and has tissue destructive effects at the resection margin and base owing to electrocautery. Despite these qualities, the “CARE” study demonstrated an IRR of 17.3% for HSP of sessile colonic polyps of 10–20 mm [56]. Furthermore, the use of electrocautery carries risks of thermal deep mural injury (DMI) and delayed PPB. Submucosal injection prior to HSP delineates the size and lateral margins of the lesion and assists with visual confirmation of the adequacy of clearance of the deep and lateral resection margins [57]. Submucosal injection expands the submucosal



► **Fig. 7** Endoscopic images of two sessile serrated lesions (SSLs) demonstrating focal dysplasia: **a, c** on high definition white-light endoscopy, showing relatively homogeneous surfaces (yellow arrows) and focal demarcated areas with adenomatous pit pattern (NICE type II; white arrows) consistent with dysplasia within SSL; **b, d** on narrow-band imaging.

layer and provides a protective cushion that reduces, but does not completely negate, the risk of electrocautery-related DMI. UEMR was shown, in one RCT, to have higher rates of R0 and en bloc resection compared with submucosal injection and HSP for polyps of 10–20 mm, with no significant difference in AEs (2.8% vs. 2.0%) [58].

7.3.2 Cold snare polypectomy for polyps of 10–19 mm

Recent research has focused on the safety and efficacy of piecemeal cold snare polypectomy (pCSP) for sessile polyps of 10–19 mm [59–63] (► **Fig. 7**). En bloc resection is usually not achievable for polyps of 10–19 mm using CSP owing to the failure of tissue transection for polyps of this size in the absence of electrocautery, so CSP was not previously recommended for polyps in this size range [64]. However, increasing recognition that en bloc resection is not required for most polyps, together with the ability of pCSP to almost entirely remove the risk of DMI or delayed PPB, has made pCSP an increasingly attractive option [65, 66].

Multiple studies have shown pCSP to be effective for the removal of SSLs. Van Hattem et al., showed similar efficacy for pCSP and conventional (hot snare) EMR for large SSLs, but with no AEs for pCSP; in comparison, conventional EMR resulted in delayed bleeding and DMI in 5.1% and 3.4% of cases, respectively [67]. These favorable results for pCSP were also demonstrated for SSLs of 10–19 mm, with multiple studies confirming a better safety profile and low recurrence rates [61–63, 68].

There is less evidence for the efficacy of pCSP for flat and sessile conventional adenomas of 10–19 mm. A systematic review and pooled analysis of CSP outcomes for sessile polyps ≥ 10 mm (median size 17.5 mm) showed a complete resection rate of 99.3% [62], with the residual polyp rate for conventional

adenomas (11.1%) significantly higher than that for SSLs (1%) [62]. Therefore, despite the safety benefits of CSP, it is not presently routinely recommended for adenomatous polyps of 10–19 mm.

A recent prospective multicenter observational study of pCSP for 350 sessile polyps of 10–19 mm, mostly conventional adenomas, did however demonstrate a 2.0% IRR and a 1.7% recurrence rate at first surveillance colonoscopy [69, 70]. Submucosal injection was used in most cases. Lesions suspicious of malignancy or containing a Paris classification 0-Is component of >10 mm were not eligible for cold resection techniques. Minor AEs occurred in 3.4% of patients, with no perforations. Although this emerging evidence suggests a role for pCSP for adenomatous polyps of 10–19 mm, larger RCTs, including in community and ambulatory settings, are required. When pCSP is used, meticulous endoscopic lesion assessment is required to exclude polyps with covert deep SMI that require en bloc resection [4, 9]. Furthermore, CSP results in a superficial mural resection, with submucosal tissue found within pathology specimens in only 24% of cases, compared with 81% when HSP is used [71].

Because of uncertainty regarding the accuracy of optical diagnosis in community settings and because the risk of invasion is higher in lesions >10 mm, the guideline task force decided against recommending pCSP as a first-line resection technique currently. For carefully selected flat adenomas of 10–19 mm (granular homogeneous LNPCPs), particularly in the right colon and especially when co-morbidity levels are high, to reduce the risks of DMI and delayed post-EMR bleeding, pCSP can be suggested.

The role of submucosal injection prior to pCSP has been studied, with safety and efficacy demonstrated, particularly for SSLs of 10–20 mm [63]. In comparison, studies that evaluated pCSP without submucosal injection for SSLs demonstrated higher, though still acceptable, recurrence rates [61, 72]. Therefore, submucosal injection is not essential prior to pCSP, but should be considered to better delineate the polyp margins and adequacy of clearance post-polypectomy, particularly if dye is included in the injectate. Submucosal injection also facilitates easier cold snare transection of the tissue, by temporarily reducing the density of the submucosal tissue [73, 74].

7.4 Endoscopic mucosal resection for large (≥ 20 mm) nonpedunculated colorectal polyps

RECOMMENDATION

ESGE recommends conventional (diathermy-based) endoscopic mucosal resection (EMR) for large (≥ 20 mm) nonpedunculated adenomatous polyps (LNPCPs). Strong recommendation, high quality of evidence.

Conventional EMR using electrocautery is the standard of care for the resection of LNPCPs [23]. In the large prospective Australian Colonic EMR (ACE) cohort, the rate of early recurrence of LNPCPs after EMR was 16%; however, many of the data were accumulated over a decade ago. More recently, the

treatment of resection margins using thermal ablation with snare-tip soft coagulation (STSC) has greatly mitigated this limitation, with recurrence rates of 1.5%–3% now reported [26, 27, 75]. EMR using electrocautery does however still carry a risk of delayed post-EMR bleeding of 6%–12% [76], and perforation is reported in 1%–2% of cases [77]. In a recent study also from the ACE cohort, the incidence of significant DMI in 3717 LNPCPs that underwent EMR was 2.7%, although all cases were managed endoscopically and 75% of patients were discharged on the same day [78].

RECOMMENDATION

ESGE suggests that underwater EMR can be considered an alternative to conventional hot EMR for the treatment of adenomatous LNPCPs.

Weak recommendation, moderate quality of evidence.

UEMR was first described in 2012. The colonic lumen is filled with water, instead of gas, and the lesion is strangled and resected with an electrosurgical snare without submucosal injection. An RCT of UEMR (n=81) vs. conventional EMR (CEMR; n=76) reported a better en bloc resection rate (33% vs. 18%; $P=0.05$) and R0 resection rate (32% vs. 16%; $P=0.03$) for LNPCPs of 20–40 mm, a lower recurrence rate (6% vs. 43%; $P=0.03$) for LNPCPs of 30–40 mm, along with a shorter procedure time (7 vs. 13 minutes; $P=0.003$) and comparable safety including delayed bleeding (2.6% vs. 1.2%; $P=0.66$) and perforation (0% vs. 0%) [22]. Another RCT comparing UEMR and CEMR for 311 LNPCPs showed comparable recurrence rates overall (9.5% vs. 11.7%), but lower recurrence with UEMR for LNPCPs of 20–30 mm (3.4% vs. 13.1%) [79]. The other two RCTs, including lesions <20 mm, reported similar outcomes [80, 81]. One meta-analysis compared UEMR and CEMR for the removal of LNPCPs [82], and six meta-analyses reported UEMR and CEMR for LNPCPs in their subgroup analysis [83–88]. Results for en bloc and complete resection, and recurrence rates are mixed across trials, but UEMR appears comparable with CEMR. Regarding AEs, two subgroup analyses in meta-analyses for LNPCPs of any size reported comparable results between UEMR and CEMR [85, 87]. In summary, UEMR has shown similar efficacy for resection, similar AE rates, and shorter procedure times when compared with CEMR for LNPCPs. Therefore, UEMR can be considered an alternative to conventional hot EMR for the treatment of LNPCPs.

RECOMMENDATION

Endoscopic submucosal dissection may also be suggested as an alternative for removal of LNPCPs of ≥ 20 mm in selected cases and in high-volume centers.

Weak recommendation, low quality of evidence.

The main advantages of ESD compared with EMR are higher rates of en bloc resection and lower rates of recurrence. Disadvantages are a longer procedure time, a higher complication rate, and a steep learning curve, especially for Western endoscopists [89]. According to the ESGE ESD Guideline [30], colorectal ESD may be considered for lesions with a high suspicion of limited SMI, based on the lesion's morphology. In a recent RCT, piecemeal EMR and ESD were both effective to treat patients with LNPCPs, but the median time to complete an EMR in this study was 14.5 minutes compared with 47 minutes for ESD [90]. The resources and opportunity costs associated with endoscopic resection are also important to consider (i.e. the advantage of the possibility of same-day discharge after EMR). After ESD, usually all patients remain in the hospital for at least one night before discharge [91]. In a cost-effectiveness analysis, selective ESD was the preferred treatment strategy for lesions with a high suspicion of SMIC [92]. Universal ESD cannot be justified beyond high risk rectal lesions.

RECOMMENDATION

ESGE recommends that, after piecemeal EMR of LNPCPs, the resection margins should be treated by thermal ablation using snare-tip soft coagulation (STSC) to prevent adenoma recurrence.

Strong recommendation, high quality of evidence.

RECOMMENDATION

ESGE recommends that, where complete snare excision cannot be achieved, the optimal method for adjunctive removal of residual adenoma is hot avulsion or cold avulsion with adjuvant snare-tip soft coagulation (CAST). Adjunctive techniques such as CAST or hot avulsion should only be used to remove residual neoplasia that is not amenable to snare resection.

Strong recommendation, moderate quality of evidence.

RECOMMENDATION

ESGE recommends against argon plasma coagulation and STSC to treat visible residual neoplasia because of its proven lack of efficacy.

Strong recommendation, moderate quality of evidence.

RECOMMENDATION

ESGE recommends that successful EMR should be defined by: the lack of endoscopically visible remnant neoplastic tissue at the mucosectomy site; histologic assessment of the specimen; and the absence of recurrence at the first surveillance colonoscopy at 6 months.

Strong recommendation, moderate quality of evidence.

► **Table 2** Adjunctive techniques for the removal of residual neoplasia that is not amenable to snare resection.

Technique	Lesion size, mm; type	Advantages	Disadvantages
Hot avulsion	<5–10	Easy to apply	Post-polypectomy syndrome, cauterization of the specimen
CAST	<5–10	Easy to apply, inexpensive	Not easy to use for larger lesions
Underwater EMR	<15–20	Easy, inexpensive	Not much evidence as an adjunctive treatment
Cap-assisted EMR	>15; nonlifting	Radical for larger lesions	Risk of damage to the muscularis propria
EFTR	<15	Can be used for difficult locations such as diverticula	Costly, risks of intra- and post-procedural perforation, and appendicitis
ESD	All sizes; nonlifting	En bloc resection and high rate of R0 resection	Very difficult, costly, high risk of perforation

CAST, cold-forceps avulsion with adjuvant snare-tip soft coagulation; EMR, endoscopic mucosal resection; EFTR, endoscopic full-thickness resection; ESD, endoscopic submucosal dissection.

There are different causes for incomplete resection of LNCPs, of which submucosal fibrosis with nonlifting and difficult access are the most important. For successful EMR, it is important to remove all visible neoplasia with snare resection techniques. Adjunctive treatment techniques are considered inferior and therefore are a final resort for removing residual neoplasia. At the present time, there is insufficient information to unequivocally guide the choice of a specific adjunctive treatment modality; however, if residual neoplasia cannot be removed with standard snare-based resection techniques, avulsion techniques have provided promising results [93].

There are different techniques that are used to treat residual neoplasia (► **Table 2**). Argon plasma coagulation should not be used as it has been demonstrated to be ineffective and is an established risk factor for recurrence [24,93]. The majority of residual neoplasms are unifocal and small, and therefore hot or cold avulsion is logical and technically feasible [24]. Hot avulsion for visible residual adenoma was shown to have equal recurrence rates to polyps managed by EMR alone where adjunctive treatment was not required (17.5% vs. 16%, respectively) [94]; however, hot avulsion was associated with a trend toward higher rates of delayed hemorrhage (5.35% vs. 2.58%) and post-polypectomy syndrome (1.8% vs. 0.47%).

Cold avulsion with either snare or cold forceps followed by ablation has been shown to be very effective for recurrence (nonlifting tissue) [93]. It seems likely that this technique might be equally as effective as hot avulsion, but perhaps associated with a lower risk of thermal damage to the muscularis propria; however, a formal comparison of the two techniques as adjunctive treatment for residual neoplasia at the baseline EMR is lacking. Hot or cold avulsion of residual neoplasia >15 mm is time-consuming and technically challenging, although such extensive areas of residual neoplasia should be very infrequent with high quality EMR practice. A recent paper showed that suction of the target area into the cap through a 10-mm snare may be successful in grasping larger target areas and thereby limiting the number of large nonlifting areas [95]; however, perforation was encountered, although this could be treated with endoscopic clip closure in all cases.

RECOMMENDATION

ESGE recommends piecemeal cold EMR for SSLs of ≥ 20 mm without suspected dysplasia.
Strong recommendation, moderate quality of evidence.

RECOMMENDATION

A suspected area of dysplasia within a large SSL should be resected en bloc by hot EMR.
Strong recommendation, moderate quality of evidence.

RECOMMENDATION

ESGE suggests cold snare piecemeal EMR for carefully selected large (≥ 20 mm) flat adenomas (granular homogeneous LSLs), mostly in the right colon, and particularly when co-morbidity levels are high to reduce the risks of deep mural injury and delayed post-EMR bleeding.
Weak recommendation, low quality of evidence.

Recent studies have demonstrated that pCSP is feasible, safe, and effective for large SSLs of ≥ 20 mm [61, 63, 67, 96]. In a large retrospective cohort study, the safety and efficacy of pCSP for large SSLs of > 20 mm were compared with a historic cohort of similar sized SSLs that were resected by CEMR [67]. Of 562 large SSLs (≥ 20 mm), 156 were treated by pCSP and 406 by CEMR. Technical success was equivalent in the two groups (100.0% [n = 156] vs. 99.0% [n = 402]). No AEs occurred with pCSP, whereas delayed bleeding and DMI were encountered in 5.1% (n = 18) and 3.4% (n = 12) of large SSLs treated by CEMR, respectively. Recurrence rates following pCSP were similar to CEMR at 6 months (4.3% vs. 4.6%) and 18 months (2.0% vs. 1.2%).

There are limited data regarding the safety and efficacy of cold snare piecemeal EMR for large sessile conventional adenomas. In a recent retrospective Australian study, cold snare

piecemeal EMR was successfully performed on 204 polyps of ≥ 20 mm (33% adenomas, 65% sessile serrated adenomas/lesions); there were no serious AEs [97].

It is now well established that prophylactic clip closure of the mucosal defect after EMR for LNPCPs in the right colon reduces the risk of delayed bleeding from 9%–11% to 3% [98–100]; however, modelling studies and decision tree analysis have shown that prophylactic clipping may not be cost-effective at current clip prices [101]. Therefore, the use of cold snare piecemeal EMR may be a cost-effective alternative to conventional EMR as large lesions removed by this technique do not require clipping because of the negligible rates of delayed bleeding and DMI.

RCT data for cold snare EMR of large sessile adenomatous polyps is soon to be reported from a number of trials.

RECOMMENDATION

ESGE recommends that, after conventional EMR of LNPCPs, resection margins should be treated by thermal ablation using STSC to prevent adenoma recurrence. Strong recommendation, high quality of evidence.

The goal of EMR for LNPCPs is the complete excision of all visible adenoma. There is no role for thermal ablation of visible residual adenoma as it has been proven to be ineffective [25]. In a multicenter RCT by the ACE consortium, 420 patients with LNPCPs (mean size 38mm) were randomized to thermal ablation of the post-EMR mucosal margin or not. Recurrence at 6-month surveillance was reduced from 21% to 5% [26]. A subsequent prospective international trial of over 1000 LNPCPs reported recurrence in 1.4% for those who received complete thermal ablation [27]. High quality EMR is an essential first step before thermal ablation of the margin. Meta-analysis data for STSC of the post-EMR defect margin of LNPCPs has not been as favorable as the larger expert studies above, underpinning the critical role of optimal EMR technique as the first line to achieve negligible recurrence. One meta-analysis containing two RCTs and four cohort studies, with 2122 patients, showed overall pooled odds of adenoma recurrence at 6-month surveillance for post-EMR STSC compared with no STSC of 0.27 (95%CI 0.18–0.42; $I^2=0\%$; $P<0.001$) [102]. The pooled rate of adenoma recurrence at 6-month surveillance in the post-EMR STSC cohort was 7%, in comparison with 21% when no adjuvant therapy was applied. A randomized in vivo porcine study has demonstrated, by blinded histopathologic analysis, that STSC provides more uniform and consistent ablation than argon plasma coagulation [103]. Therefore, at the present time STSC is the preferred method for margin thermal ablation.

RECOMMENDATION

ESGE suggests against routine prophylactic clipping after conventional polypectomy for lesions <20 mm and for lesions ≥ 20 mm in the left colon because of a lack of evidence.

Weak recommendation, low quality of evidence.

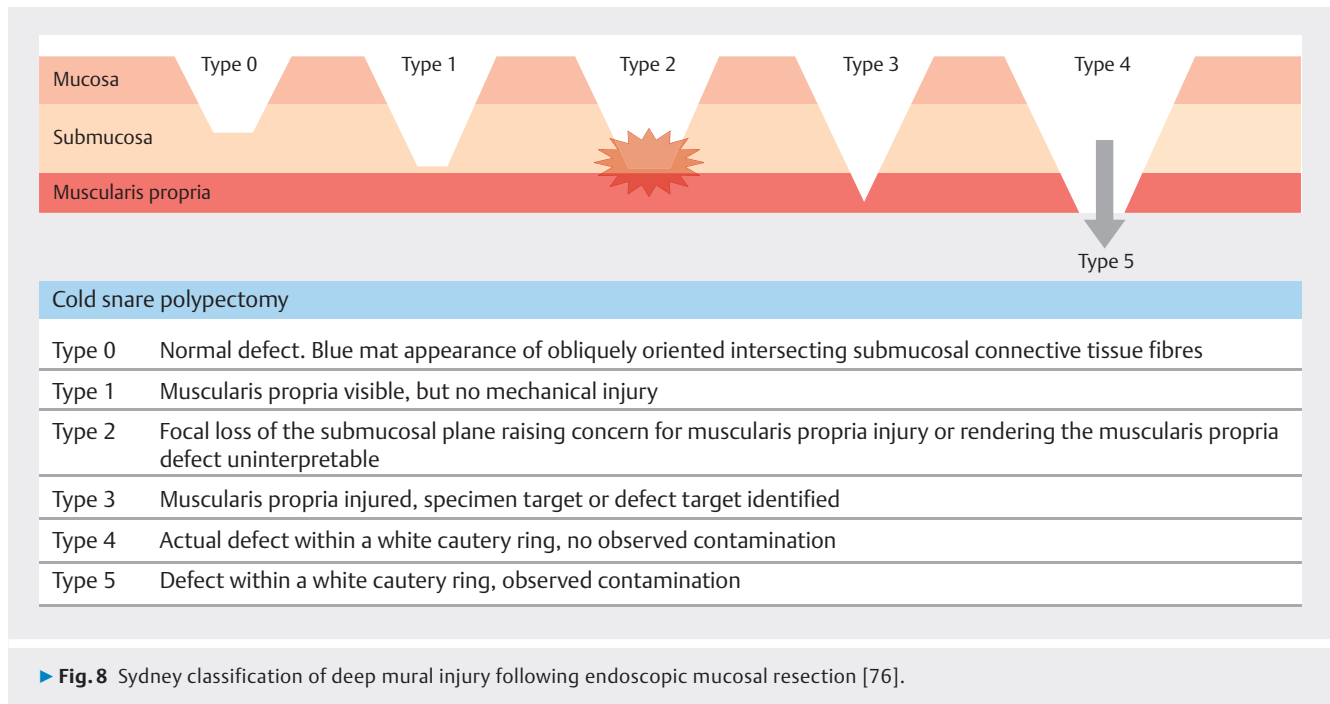
RECOMMENDATION

ESGE recommends prophylactic clip closure of the mucosal defect after conventional EMR of LNPCPs in the right colon.

Strong recommendation, high quality of evidence.

Several RCTs have evaluated the efficacy of clip closure of the mucosal defect after CEMR of LNPCPs. Pohl et al. randomly assigned 919 patients to either post-polypectomy endoscopic clip closure or no clip closure [99]. The primary outcome of this study was the incidence of PPB, which occurred in 3.5% of patients in the clip group vs. 7.1% in the control group (absolute risk difference 3.6 percentage points, 95%CI 0.7–6.5 percentage points). In a subgroup analysis of 615 patients (66.9%) with an LNPCP in the proximal colon, the risk of PPB in the clip group was 3.3% vs. 9.6% in the control group (absolute risk reduction 6.3 percentage points, 95%CI 2.5–10.1 percentage points). Gupta et al. evaluated the use of prophylactic clip closure in preventing clinically significant post-EMR bleeding in the right colon [100]. Patients referred for EMR of LNPCPs in the right colon were randomly assigned to clip closure or no clip closure. The study's primary end point was the incidence of clinically significant post-EMR bleeding. A total of 231 patients were randomly assigned and, by intention-to-treat analysis, clinically significant post-EMR bleeding was significantly less frequent in the clip group than in the no clip group (4/118 [3.4%] vs. 12/113 [10.6%]; $P=0.03$) giving an absolute risk reduction of 7.2 percentage points (95%CI 0.7–13.8 percentage points) and number needed to treat to prevent one post-EMR bleed of 13.9. Another European RCT found that clip closure reduces the delayed bleeding risk when there is a substantial risk of bleeding and a complete closure of the mucosal defect is achieved [98].

A meta-analysis of individual patient data ($n=1150$) from four randomized trials assessing the efficacy of prophylactic endoscopic clipping to prevent AEs following EMR of proximal LNPCPs reported that clipping prevented clinically significant post-EMR bleeding (OR 0.31, 95%CI 0.17–0.54) [104]. Clipping was not associated with perforation or abdominal pain. These multicenter RCTs and the meta-analysis provide strong evidence that endoscopic clip closure of the mucosal defect after resection of LNPCPs in the proximal colon significantly reduces the risk of PPB.



Factors associated with the incidence of PPB are either related to polyp characteristics (size, morphology, and location of the polyp) or to the patient's health status (age >65 years, presence of hypertension or renal disease, and the use of anti-coagulants). PPB complicates 6%–7% of CEMRs of an LNPCP. Data from EMR of sessile colorectal polyps ≥ 20 mm in size showed that PPB was associated with proximal colon location, use of an electro-surgical current not controlled by a microprocessor, occurrence of intraprocedural bleeding (IPB), and aspirin use. In the Munich Polypectomy Study, polyp size and proximal location of the polyp were risk factors for AEs such as PPB. A meta-analysis has shown that the risk of PPB was significantly increased for patients taking clopidogrel. Two studies have designed predictive scores for the risk of bleeding and both scores have been evaluated and optimized in a cohort of more than 2000 patients [101, 105, 106]. Taking into account the lesion size, proximal location, co-morbidities, and anti-platelet or anticoagulant therapy, the risk of delayed bleeding can be estimated, which can allow the application of prophylactic measures in high risk patients.

A cost–efficacy decision tree analysis of prophylactic clip placement after endoscopic removal of LNPCPs has shown that this strategy appears to be cost-effective for patients who receive antiplatelet or anticoagulation therapy [107]. Another study used a combination of risk factors to show that, in high risk patients, clipping can be cost-effective and even cost-saving [108].

Therefore, the use of mechanical prophylaxis in certain high risk cases after standard polypectomy or EMR should be individualized, based on patient or polyp risk factors.

7.4.1 Assessment of perforation risk

RECOMMENDATION

ESGE recommends careful inspection of the post-resection mucosal defect, using the Sydney DMI classification, to identify features of, or risk factors for, immediate or delayed perforation. Where these risk factors are identified, clip closure should be performed.

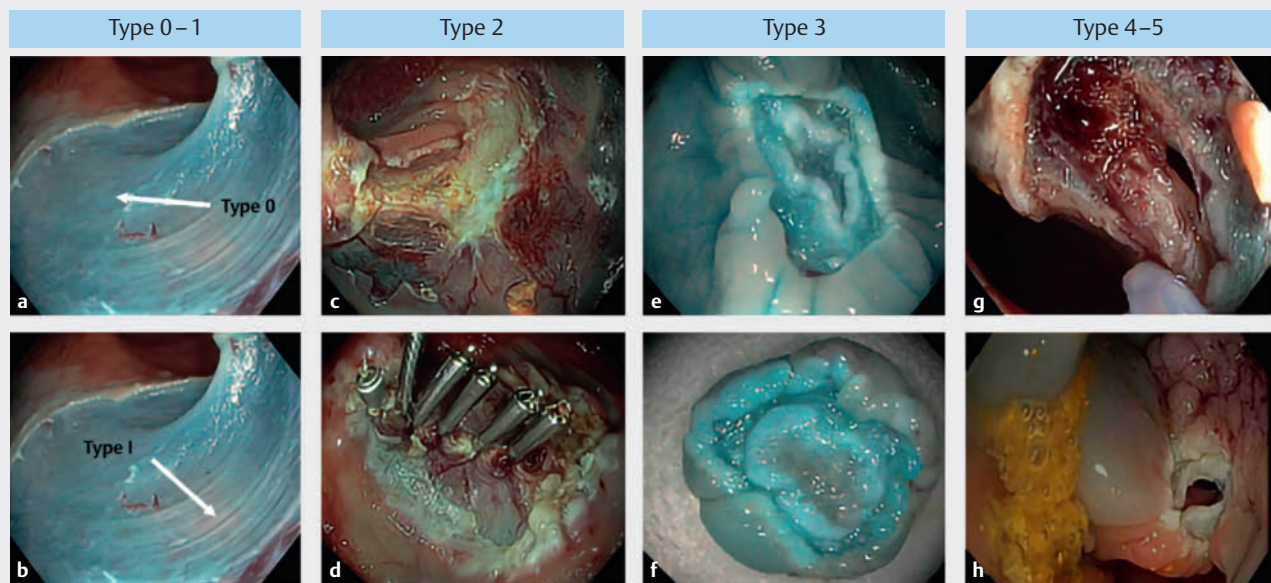
Strong recommendation, moderate quality of evidence.

Acute iatrogenic perforation related to gastrointestinal endoscopy is defined as the recognition of gas or luminal fluids outside the gastrointestinal tract, or any endoscopically identified definite visible sign of perforation during, or in time related to, the endoscopy [109]. Two meta-analyses and an international cohort have reported acute iatrogenic perforation rates ranging from 0.9% to 2.7% following colonic EMR [78, 110, 111].

Most perforations detected during colonoscopy can be effectively treated by endoscopic means using through-the-scope (TTS) clips [78, 109, 112, 113]. In a British case series describing post-perforation outcomes (82/117 evaluated cases were associated with polypectomy or EMR), TTS clips were successfully used to close defects in 83.3% of cases where the perforation was visualized by the endoscopist [112]. Most delayed perforations (>4 hours after the procedure) require immediate surgical treatment [109].

After all endoscopic resections have been completed, careful inspection of the mucosal defect should be performed. The Sydney DMI classification was proposed by Burgess et al., who evaluated 911 LNPCPs treated by EMR [77] (► **Fig. 8**). This clas-

Sydney classification of deep mural injury (DMI)



► **Fig. 9** Representative endoscopic images for the Sydney deep mural injury (DMI) classification after colonic endoscopic mucosal resection showing: **a** type 0, no visible muscle, intact submucosa, uniform blue staining; **b** type 1, an area of visible intact uninjured muscularis propria within the same defect; **c,d** type 2 DMI with; **c** focal loss of the submucosal plane due to submucosal fibrosis, with muscularis propria injury not excluded; **d** after complete clip closure of the area of DMI; **e,f** type 3 DMI with; **e** the defect target sign, with a white cautery ring of muscularis propria excision surrounded by normal submucosa and a white cautery ring of mucosal resection creating the visual effect of the target; **f** the target appearance on the resected specimen; **g** type 4, defect in the muscularis propria with a visible hole; **h** type 5, defect in the muscularis propria with a visible hole and impending contamination.

sification evaluates the appearance and integrity of the muscularis propria after EMR and various extents of DMI (► **Fig. 9**). The risk of perforation following a type 1 DMI is considered low and treatment with TTS clips is not required. TTS clip placement in cases of type 2 injury is advised to reduce the risk of delayed perforation. The “target sign” (type 3 DMI) is characterized by a white-to-gray circle of resected muscularis propria on the transected undersurface of the specimen surrounded by blue-stained submucosa from the injection solution [114]. In these cases, clip closure is strongly recommended to prevent delayed perforation. Types 4 and 5 DMI correspond with complete transection of the muscle layer and should immediately be closed by endoscopic means.

Detection of intraprocedural perforation may be facilitated by the use of topical submucosal chromoendoscopy, a simple technique that confirms the level of resection [115]. Nevertheless, the occurrence of a type 4 or 5 DMI should not preclude the complete resection of the polyp, provided the patient is stable. Needle decompression of a capnoperitoneum may be needed. En bloc snare excision for lesions ≥ 25 mm [116], with high grade dysplasia/early cancer, and a transverse colon location have been demonstrated to be risk factors for DMI [77].

7.4.2 Management of the nonlifting polyp

RECOMMENDATION

ESGE recommends that when a lesion appears suitable for endoscopic resection and does not show signs of deep submucosal invasion, but does not lift with submucosal injection, referral should be made to an expert endoscopist.

Strong recommendation, moderate quality of evidence.

RECOMMENDATION

ESGE recommends that, in addition to conventional EMR, adjunctive techniques including hot or cold avulsion (CAST) be considered as treatment options in the management of nonlifting areas within LNPCPs.

Strong recommendation, moderate quality of evidence.

The nonlifting sign was described in 1994 and at that time was strongly linked with deep SMIC [117]; however, it is now well established that benign lesions may lift poorly owing to fibrosis related to lesion biology (nongranular LNPCPs), previous manipulation such as biopsies or prior resection attempts, or sublesional tattoo dispersion [17, 118]. Therefore,

nonlifting should not be assumed to be indicative of SMIC, but high quality optical diagnosis is mandatory to rule out deep SMIC before endoscopic treatment of a nonlifting lesion is attempted.

EMR-based techniques, with or without avulsion, have shown good results in the management of nonlifting benign lesions. Given that injection and snare resection alone may not be effective in nonlifting lesions, additional treatments such as hot avulsion or CAST have been introduced [94]. Tate et al. demonstrated, in a prospective observational study, that CAST was safe and effective in the treatment of 117 nonlifting lesions, with no delayed perforation seen [93].

Recently, a single center prospective cohort evaluated the performance of EMR for previously attempted LNPCPs in 158 lesions (median size 30mm), drawn from a cohort of 1134 LNPCPs referred to a tertiary center for EMR [119]. The technical success rate was 96% overall. CAST was used for nonlifting tissue in 46.2% of cases. Recurrence was 7.8% at 6 months, comparing favorably with the rate of 10.3% in the naïve cohort. UEMR might be another alternative in the management of nonlifting lesions because submucosal injection is avoided; it has shown feasibility and good results in a retrospective study [120], but more data are needed for this indication.

Alternatively, for en bloc resection of nonlifting lesions ≤ 2 cm, endoscopic full-thickness resection (EFTR) has shown good efficacy, but the risk of delayed perforation and need for surgery are 2.5% and 2.2%, respectively, which is well above the rates seen with other techniques, where the need for surgery for AEs is rare [121–124]. For en bloc resection of larger nonlifting lesions, ESD may be an option in expert centers, but it is (much) more challenging than ESD for lesions with good lifting [125, 126]. Finally, endoscopic debridement for nonlifting colorectal lesions has been described but further studies are needed regarding its efficacy, safety, and long-term results [127, 128].

7.4.3 When should EMR be performed by an expert endoscopist and when should other non-snare techniques

RECOMMENDATION

Large (≥ 20 mm) sessile and laterally spreading or complex polyps should be removed by an appropriately trained and experienced endoscopist, in an appropriately resourced endoscopy center.

Strong recommendation, moderate quality of evidence.

RECOMMENDATION

ESGE recommends that polyps without characteristics of deep submucosal invasion should not be referred for surgery, without consultation with an expert endoscopy center for evaluation for polypectomy/EMR/ESD.

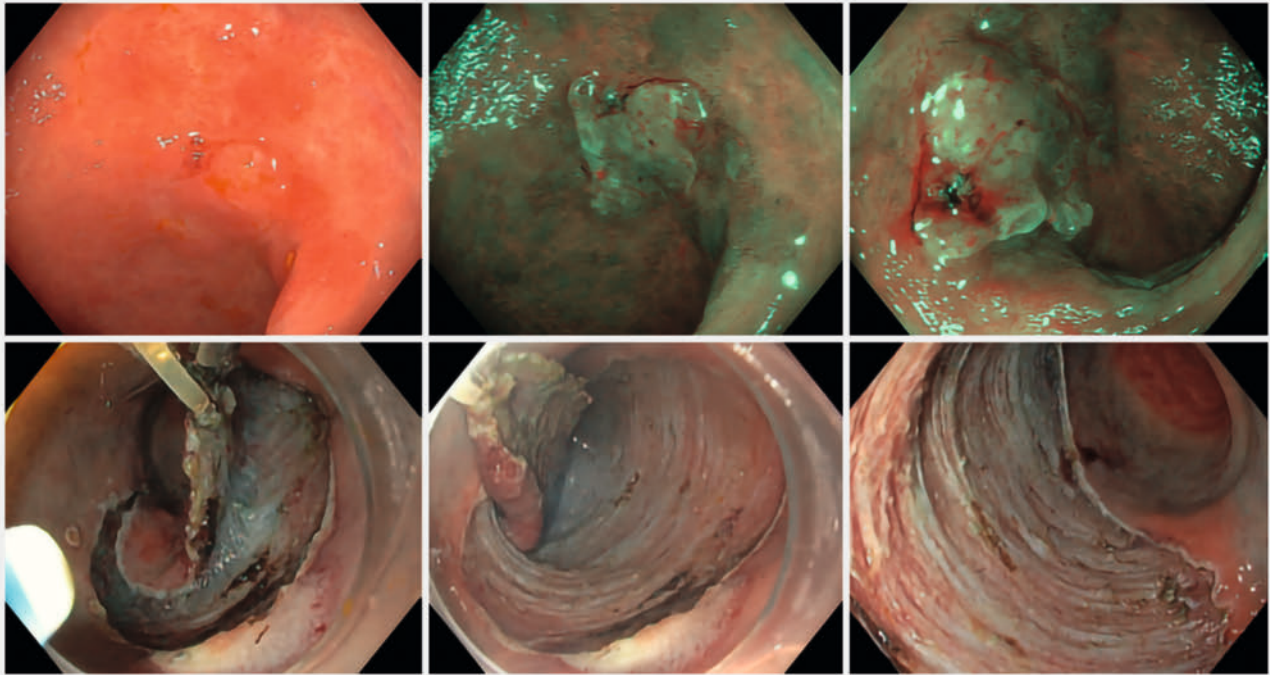
Strong recommendation, moderate quality of evidence.

The size, morphology, site, access (SMSA) polyp scoring system is a method of stratifying the difficulty of polypectomy through assessment of the four domains; SMSA stage 4 polyps are complex [116]. Technical failure, complications, and the risk of recurrence at 6 months are all known to increase with increasing complexity of colorectal polyps [116, 129]. Complexity of polyps also causes referral for primary surgery of noninvasive polyps with a low risk of early cancer (especially large LNPCPs in the proximal colon) [130, 131]. It has also been shown that successful polypectomy can be achieved at a second attempt in expert tertiary centers after a failed EMR at baseline, with the use of ancillary techniques such as CAST, with success rates comparable to the rates reported for primary resections [119]. When EMR is performed by endoscopists at a population level, as LNPCP size increases, technical success decreases and the recurrence rate increases [132].

Polyps without characteristics of deep SMI have a very high likelihood of being successfully removed endoscopically at expert centers, and patients with these should be offered a consultation to discuss endoscopic management before proceeding to surgery. A recent study showed a decrease in surgical resections after implementing a referral network for benign colorectal polyps [133].

Patients at high risk for AEs should be treated in a setting with immediate access to an acute intervention team, surgical support, and specialized equipment for advanced hemostasis (hemostatic forceps) and closure of perforations [23, 27, 78]. In a large multicenter study of 1050 patients treated by EMR for LNPCPs, no deaths occurred within 30 days; however, the predicted surgical mortality rate calculated by two independent well-validated scoring systems was 3.3% [134]. Given that endoscopic therapy is less morbid and less expensive than surgery, and can be performed as an outpatient treatment, it should be considered as first line for most patients with these lesions.

As the complexity of EMR increases (SMSA category 4), the risks of significant complications such as IPB and perforation grow [116]. The endoscopy facility should be able to manage these complications by the use of auxiliary tools, such as hemostatic forceps, or closure devices, such as endoscopic clips, and this is particularly important for patients with significant comorbidity. Longer procedure times require prolonged sedation, which may increase the risk of cardiovascular and pulmonary events although, unlike surgery, patients with advanced comorbidity have been demonstrated to have limited if any increase risk of serious AEs after EMR in expert centers. There should be sufficient support (surgery, interventional radiology, urgent intervention team) to manage these complications if they occur.



► **Fig. 10** Endoscopic images showing a subtle nongranular laterally spreading lesion in the sigmoid colon with focal disruption of the pit and microvascular patterns, J-NET 2B, indicative of possible early submucosal invasion, which was treated with wide en bloc excision by endoscopic submucosal dissection with traction. JNET, Japan NBI Expert Team.

RECOMMENDATION

En bloc resection techniques, such as en bloc EMR, ESD, endoscopic intermuscular dissection, endoscopic full-thickness resection (EFTR), or surgery should be the techniques of choice in cases with suspected superficial invasive carcinoma, which otherwise cannot be removed en bloc by standard polypectomy or EMR. Strong recommendation, moderate quality of evidence.

When superficial invasive carcinoma is suspected, endoscopic treatment may be considered curative if the histology shows a complete en bloc R0 resection, well-differentiated adenocarcinoma, and <1 mm depth of SMI (SM1) with no lymphovascular invasion and no tumor budding [30] (► **Fig. 10**). En bloc resection allows optimal histologic assessment of these factors including R0 resection. En bloc EMR is generally limited to lesions of 20 mm in size, with larger lesions usually requiring ESD or surgery to achieve an en bloc resection [116]. The risk of incomplete resection is lower for lesions <20 mm in size; however, a recent meta-analysis showed a substantial rate of incomplete resection (20.8% of snare resections) for lesions of 10–20 mm [135]. Therefore, the risk for SMIC has to be estimated before treatment to choose the ideal resection method and to decide whether en bloc resection is needed [30]. A recent

study showed some limitations of optical diagnosis for JNET 2B lesions. Optical diagnosis alone has limited utility; however, when incorporated with morphology and lesion location, the sensitivity and specificity increase. Therefore the JNET classification should be used in the context of lesion location and morphology to select the optimal resection technique [136].

RECOMMENDATION

ESGE suggests that EFTR can be considered for endoscopic resection of lesions that otherwise cannot be removed by standard polypectomy, CAST, EMR, or ESD (e.g. nonlifting lesions without signs of submucosal invasion, lesions involving the appendiceal orifice or diverticula). Weak recommendation, low quality of evidence.

RECOMMENDATION

ESGE suggests that EFTR can be considered as a treatment option for residual/recurrent lesions after resection of superficial invasive carcinoma. Weak recommendation, low quality of evidence.

EFTR allows endoscopic resection of colorectal lesions including the entire colorectal wall. A multicenter study including 181 difficult colorectal lesions (nonlifting adenomas that were predominantly pretreated [$n=104$], adenomas involving the appendiceal orifice [$n=34$] or a diverticulum [$n=5$], superficial invasive cancers that were predominantly pretreated [$n=15$], and subepithelial lesions [$n=23$]) showed that the R0 resection rate was 87.0% for subepithelial lesions, being significantly higher for lesions of all types when <20 mm in diameter (81.2% vs. 58.1%; $P=0.004$) [121]. The AE rate was 9.9%, with a 2.2% rate of emergency surgery.

In a German study, EFTR for early CRC resulted in a 71.8% R0 resection rate [137]. When residual/recurrent lesions after previous resection were treated, the R0 resection rate was 87.5% and the rate of histopathologic low risk features was 84.1%. In contrast, for untreated lesions with a nonlifting sign, the R0 resection rate was 60.9% with histopathologic low risk features in only 16.3%. In a recent Dutch multicenter study including 330 EFTRs (132 primary resections and 198 secondary scar resections after incomplete T1 CRC resection), the overall technical success, R0 resection, and curative resection rates were 87.0% (95%CI 82.7%–90.3%), 85.6% (95%CI 81.2%–89.2%), and 60.3% (95%CI 54.7%–65.7%), respectively [122]. The curative resection rate was 32.0% (95%CI 24.2%–40.9%) for primary treatment and 79.2% (95%CI 72.6%–84.5%) after secondary treatment. Risk stratification was possible in 99.3%.

A meta-analysis including 1936 patients treated with EFTR (57.7% adenomas, 21.2% T1 cancers) reported a technical success rate of 87.6% (95%CI 85.1%–89.8%), R0 resection rate of 78.8% (95%CI 75.7%–81.5%), AEs in 12.2% (95%CI 9.3%–15.9%), and recurrences in 12.6% (95%CI 11.1%–14.4%) during an average (SD) follow-up of 20.1 (3.8) weeks [138]. The R0 resection rate was significantly lower (OR 0.3, 95%CI 0.2–0.6) and the AE rate was significantly higher (OR 3.5, 95%CI 1.8–7.2) for lesions >20 mm.

These data indicate clearly that the best indication for EFTR is recurrent/residual disease of previously treated benign disease; however, avulsion techniques are less expensive, highly effective, and much safer.

7.4.4 Tattooing of lesions

RECOMMENDATION

ESGE recommends that lesions that may need to be located at future surgical procedures, polypectomy sites in cases where cancer is suspected, or where subsequent identification of the endoscopic scar location may be challenging should be tattooed during colonoscopy, with the relationship between the tattoo and the lesion documented in photos and writing.

Strong recommendation, moderate quality of evidence.

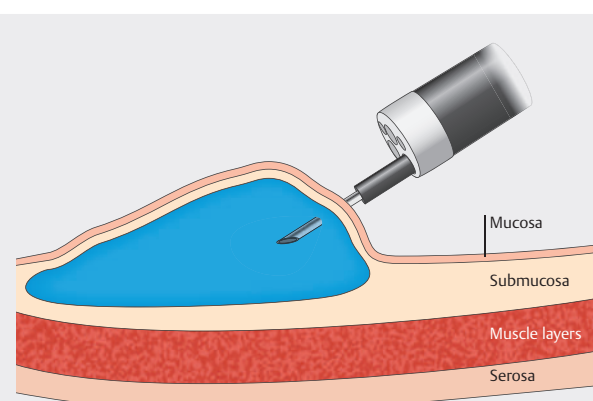
RECOMMENDATION

ESGE recommends that tattoos be placed ≥ 3 –5 cm anatomically distal (anal side) to the lesion. In order to locate polyps or scars at a subsequent endoscopy, in general only one tattoo is needed.

Strong recommendation, moderate quality of evidence.

Tattooing is performed to enable future identification of lesions that need to be endoscopically or surgically treated. The formation of a saline bleb in the submucosal layer of the colon prior to tattoo injection should be done with a volume of 0.5–1 mL of normal saline (► Fig. 11). The volume of each tattoo should not exceed 1 mL per injection site. Cecal, ileocecal valve, and rectal locations are readily identifiable and therefore tattooing is not required at these sites.

Since the last guideline was published, several studies have confirmed the usefulness of tattooing for relocation, especially for surgery. A meta-analysis of 38 trials assessed location errors for colonic lesions treated with laparoscopic or open surgery [139]. From 18 studies (2578 patients), the location error of conventional colonoscopy was assessed to be 15.4% (95%CI 12%–18.7%); in 17 studies (643 patients), the location error rate with colonoscopic tattooing was significantly lower at 9.5% (95%CI 5.7%–13.3%; mean difference 5.9 percentage points, 95%CI 0.65–11.14 percentage points; $P=0.03$). A recent RCT including 117 patients showed a significant reduction in mean (SD) lesion identification time (3.4 [1.4] vs. 11.8 [3.4] minutes; $t=-14.07$; $P<0.001$) and operation time (155.7 [44.5] vs. 177.2 [30.2] minutes; $t=-2.48$; $P=0.02$) for those with a tattoo compared to those without [140]. In addition, there was a numerically lower rate of first positive resection margins



1. Prime needle with saline
2. Advance needle through endoscope
3. Approach and insert needle into mucosa at an oblique angle
4. Create saline bleb (to reduce risk of transmural injection)
5. Inject 0.5–1 mL of tattoo per bleb

► Fig. 11 Schematic of the technique for tattooing with a saline bleb. Image credit: Lisa-Maria Rockenbauer.

in the tattoo group [0 vs. 4.5% (1/22); chi-squared=0.62; $P=0.48$]. Of interest, a retrospective cohort study showed that tattooing leads to a significant reduction in the need for repeat preoperative colonoscopy (OR 0.48, 95%CI 0.34–0.68; $P<0.001$) [141], indicating that this is cost-effective [142].

Although tattooing is still often performed after endoscopic resection, a recent prospective observational cohort study showed that, for 1023 LNPCPs, the EMR scar could be located without the need for tattooing in 99.7% of cases [143].

Recently an international Delphi consensus on the appropriate use of endoscopic tattooing in the colon was published, describing different indications and the technique of injection [144] (► Fig. 11). Since this Delphi process, additional evidence has become available. Barquero et al. conducted an RCT with four groups of ink injection (two sites with 1 mL or 1.5 mL, or three sites with 1 mL or 1.5 mL), with no difference being found at the location of the tattoo during surgery [145]. The guideline task force adhered to a rather limited volume of solution (maximum 1 mL), in keeping with the Delphi consensus (0.5–1 mL). A recent RCT, including 94 patients, compared the use of sterile carbon particle suspension versus India ink [146]. The authors found a significantly higher C-reactive protein (CRP) level at 6 and 24 hours in the India ink group and significantly fewer adhesions when the sterile carbon particle suspension was used. Tattooing is also preferred to placing a clip. A recent RCT showed, in 195 patients, that successful identification of location during surgery was significantly lower in the clip group [147].

7.4.5 How can completeness of resection after snare polypectomy or EMR be proven?

RECOMMENDATION

ESGE recommends that endoscopic cure for lesions resected by EMR should be confirmed at surveillance colonoscopy using advanced endoscopic imaging. Strong recommendation, moderate quality of evidence.

When piecemeal resection of LNPCPs is performed, there is an inherent risk of residual neoplastic tissue in either the base or the margins of the defect, so careful inspection after resection is paramount. The use of magnifying endoscopy has good accuracy in detecting residual adenoma and leads to lower rates of recurrence, but is not routinely available and, in the era of margin ablation, is not likely to be necessary [148]. A recent prospective study failed to show a benefit of VCE over WLE in detecting remnants after resection of SSLs [149]. Furthermore, despite careful inspection and apparently successful endoscopic resection of the entire neoplastic mucosa, residual microscopic foci in the margins or base of defects after wide-field EMR may occur [150, 151].

8 Recurrence after endoscopic resection

8.1 What are the predictive factors for recurrence?

Recurrence after resection of colonic lesions is variable and not completely avoidable, despite rigorous technique. There is now sufficient cumulative evidence from both retrospective and prospective studies to conclude that two features reliably predict recurrence at follow-up colonoscopy: larger lesion size and piecemeal resection [26, 152–156]. This is to be expected, given the fact that positive margins are a proven risk factor for recurrence [150, 157], and that additional treatment of the margins reduces this risk. Also, the margins after diathermy may be difficult to interpret.

An attempt to integrate various features of the polyp and technique has resulted in use of the SMSA score to identify lesions that are prone to recur after EMR [116, 157, 158]. Another score (the SERT-Sydney EMR recurrence tool), based on size (≥ 40 mm), IPB, and the presence of high grade dysplasia, was shown to predict recurrence at follow-up and could be used to stratify surveillance intervals, with those without risk factors undergoing first surveillance at 18 months, and those at risk following the standard protocol of first surveillance at 6 months [151]. Significant IPB is also a recognized risk factor for recurrence.

8.2 Management of recurrence at surveillance colonoscopy

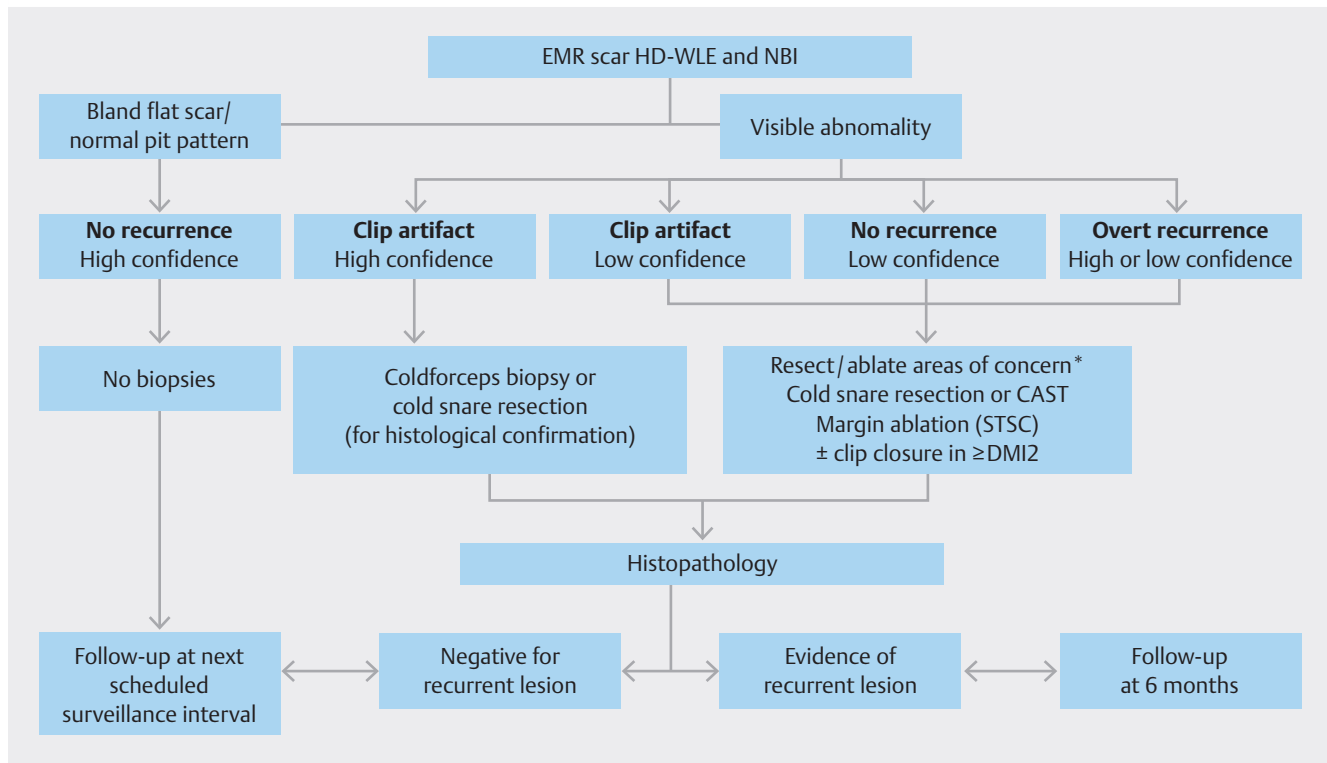
RECOMMENDATION

ESGE recommends that all visible potential residual or recurrent adenoma identified at surveillance colonoscopy is resected using a snare within the same procedure. Strong recommendation, moderate quality of evidence.

RECOMMENDATION

ESGE recommends careful optical evaluation of the post-EMR scar rather than biopsy. Weak recommendation, moderate quality of evidence.

Suspected recurrence of neoplasia at surveillance colonoscopy can generally be treated successfully in the same session, with snare-based resection as an effective first option [24] (► Fig. 12 [159]). Several alternatives are available when adequate lifting or complete removal is not possible owing to submucosal fibrosis. Single-center studies have shown that CAST is safe and effective in this case [93, 119]. The use of hot forceps avulsion has been reported as being effective and safe for difficult lesions in small retrospective cohorts [94]. More advanced techniques, such as ESD [125, 160] or EFTR [123, 161], lead to technical success and R0 resection of difficult lesions in more than 70%–80% of cases, but are more resource-intensive and expensive, and are associated with a higher risk of significant complications, including the need for emergency surgery. Recently, review of a large series of 213 EMR recurrences, drawn



► **Fig. 12** The Westmead algorithm for evaluating recurrence following endoscopic mucosal resection of lesions ≥ 20 mm [157]. EMR, endoscopic mucosal resection; HD-WLE, high definition white-light endoscopy; NBI, narrow-band imaging; CAST, cold avulsion and snare-tip soft coagulation; STSC, snare-tip soft coagulation; DMI, deep mural injury.
* The aim of treatment of recurrence is to create a flat, white denatured, nonbleeding scar (blood compromises interpretation of the scar).

from a prospective cohort of 2311 LNCPs undergoing follow-up, demonstrated successful treatment of recurrence in over 95% of cases [162]. Most of these data preceded the advent of STSC of the resection margin, which may further augment the prevention of endoscopic recurrence [162].

9 Management of adverse events

9.1 Definitions and management of bleeding

Consensus on the definition of PPB is incomplete. Definitions vary throughout the literature. For the purposes of this guideline, two terms have been used: IPB and PPB. These terms are defined as follows:

- IPB is bleeding occurring during the endoscopic procedure that persists for more than 60 seconds or requires endoscopic intervention
- PPB is bleeding occurring after the endoscopic procedure, up to 30 days post-polypectomy, that results in an unplanned medical presentation, such as an emergency department visit, hospitalization, or re-intervention (repeat endoscopy, angiography, or surgery).

9.1.1 Management of intraprocedural bleeding

RECOMMENDATION

ESGE suggests the use of endoscopic coagulation (STSC or coagulating forceps) or mechanical therapy, with or without the combined use of dilute adrenaline injection, for the treatment of IPB.

Weak recommendation, low quality of evidence.

IPB occurs in 2.8% of patients undergoing standard polypectomy and in 11.3% of patients with LNCPs treated by EMR; it is rarely serious. Vigorous irrigation, preferably by using a water-jet pump, improves visualization and may aid in the cessation of bleeding originating from small vessels [163, 164]. Adrenaline injection (1 : 10000 or 1 : 20000 dilution with saline) may be used to gain initial control of active bleeding, but should always be used in combination with a second mechanical or thermal hemostatic modality. Further management of IPB can be achieved with STSC, coagulation forceps, and endoscopic clips. STSC has been shown to be an effective method of IPB control [165], while coagulating forceps are reserved for more severe cases of IPB [163, 164].

IPB that occurs after removal of a pedunculated polyp can be managed by placing a clip or a detachable snare. When there is immediate massive IPB, the polyp snare may be used to re-

snare the remaining stalk, with temporary control of the bleeding providing time for subsequent application of a clip or detachable snare. Where a significant volume of blood is pooling and overlying the bleeding point, it can be difficult to identify and treat the precise bleeding point. In such cases, changing the patient's position so that the bleeding point is in a gravity nondependent position will enable the bleeding point to be clearly visualized and treated.

9.1.2 Management of post-procedural bleeding

RECOMMENDATION

ESGE recommends that patients admitted to hospital with PPB who are hemodynamically stable, without ongoing bleeding, may be initially managed conservatively. If intervention is required, colonoscopy should be the first-line investigation.

Strong recommendation, moderate quality of evidence.

Prevention of PPB has been discussed in previous sections of this document; however, PPB is one of the most common causes of lower gastrointestinal bleeding amenable to endotherapy [166]. Not all patients presenting with PPB require urgent colonoscopy; however, a clear means of identifying those that do has not been defined and only expert opinion exists. Patients responding to hemodynamic resuscitation should initially be clinically observed [167,168]. If bleeding persists, patients should be given adequate bowel preparation and undergo a repeat colonoscopy [167].

A recent observational study conducted at six Spanish tertiary care centers evaluated factors associated with therapeutic intervention and active bleeding during colonoscopy for patients with PPB (n=548) [169]. The authors reported that 71.9% of patients underwent repeat colonoscopy, 2.6% underwent primary angiographic embolization, and 25.5% were managed without intervention. The authors concluded that colonoscopy may be overused in PPB because active bleeding was found in only one-fifth of colonoscopies and nearly half of the patients with PPB did not require any hemostasis. Furthermore, patients treated without intervention had excellent outcomes in terms of rebleeding and transfusion requirements [169].

RECOMMENDATION

ESGE recommends that, when the polypectomy site is identified during colonoscopy for PPB and active bleeding or other high risk stigmata are identified, forceps coagulation or mechanical therapy, with or without the combined use of dilute adrenaline injection, should be performed.

Strong recommendation, moderate quality of evidence.

The optimal technique for achieving endoscopic hemostasis in cases of active PPB or with other high risk stigmata has not been determined. Hemostasis technique selection is based on the location and characteristics of the lesion, endoscopist preference and experience, and device availability. The most common methods are clipping, snare or forceps coagulation, with or without the combined use of adrenaline injection [167]. Clipping, with or without adrenaline injection, may be superior to forceps coagulation therapy as it limits further tissue injury. Caution is necessary during the application of hemostatic techniques as transmural injury from thermocoagulation and perforation during clipping have been reported, among other AEs [170]. Endoscopic band ligation has also been used to manage PPB for pedunculated or semipedunculated polyps [171].

9.2 Reporting of adverse events

Methods of collecting data on AEs following endoscopic procedures, including colorectal polypectomy, are not uniform and vary from nonsystematic self-reporting to complete registry reporting, including linkage to databases other than endoscopic ones. A uniform methodology for immediate and delayed (up to 30 days) AEs is required and studies on completeness of data are needed. Whether the choice of feedback modality (paper-based, automated telephone, online survey) impacts response rates is controversial [77, 172].

Patient-reported outcome measures are a valuable resource to capture AEs that are not recorded through any registries. Routine reporting of patient feedback within a quality assurance network revealed both a substantial number of post-colonoscopy hospital admission due to AEs that had not been registered in colonoscopy reports, and severe AEs without there having been a hospital admission [173].

Currently, no systematic audits concerning polypectomy complications are functioning outside of research studies. Optimally audit should contain: (a) immediate self-reporting by the endoscopy service; (b) a self-report by the patients on the day after colonoscopy; (c) a 30-day structured telephone interview or patient questionnaire by telephone contact if there is no face-to-face contact; and (d) linkage to a national hospitalization database. AEs should preferably be assessed in a uniform methodology within a quality assurance program.

9.3 Use of antibiotics

RECOMMENDATION

ESGE does not suggest routine use of antibiotics for conventional polypectomy or EMR in the colon. ESGE suggests prophylactic antibiotics can be considered for EMR in the distal rectum or anorectal junction, because of the direct lymphovascular drainage of the mucosa into the systemic circulation, bypassing the portosystemic circulation.

Weak recommendation, very low quality of evidence.

In a prospective observational study, prophylactic antibiotics were administered in 26 patients undergoing endoscopic management with EMR of advanced mucosal neoplasia of the anorectal junction [174]. Patients undergoing EMR of large distal rectal LSLs are at risk of significant bacteremia due to direct lymphovenous drainage into the systemic circulation, bypassing the portal venous circulation, so prophylactic intraprocedural intravenous antibiotics are suggested. Further perioperative antibiotics were not effective against post-ESD coagulation syndrome [175].

10 Management of the histology specimen

Each specimen should be put in a separate pathology container and labeled with a number. Fixation should be with buffered 10% formalin. The pathologist should measure the size of each specimen in millimeters. Adenomatous-appearing lesions can however be put in one container if they are from the same colonic segment. Large (≥ 20 mm) LSLs should be pinned to cork to optimize histologic assessment.

Ideally specimens should be placed in separate containers, one for each lesion. Where there are numerous small polyps with the same optical diagnosis (all adenomatous or all serrated) that are taken out during the same session, use of the same container for several polyps is justified if: the polyps are closely located in the same region, the endoscopist is confident in optical diagnosis, and the resections are properly performed to ensure adequate margins. This would reduce the environmental burden and costs of the examination. Where the histology is likely to differ, separate containers should be used. Piecemeal resections should be placed in a single container, unless a dominant nodule or similar requires special attention. Specimens should be clearly labelled by their anatomic location (e.g. proximal transverse or distal descending).

To optimize histopathologic assessment, resection specimens of sessile or flat lesions ≥ 20 mm should be pinned out (mucosal surface upwards) on a piece of cork or other suitable material, by inserting pins through the periphery of the specimen. For stalked polyps it is recommended that endoscopists put a needle in the stalk to make orientation easier for the pathologist.

Fixation – in the endoscopy room – should be with buffered 10% formalin. A minimum of 2–3 hours of fixation is required, while lesions > 1.5 cm are fixed overnight [176].

Pathologists should report the size in millimeters if a lesion is removed en bloc. The measurement of pedunculated polyps does not include the stalk, only the polypoid tissue.

10.1 Communication between endoscopist and pathologist

In addition to reporting the polyp characteristics, ESGE favors reporting the method of resection (snare polypectomy [cold vs. hot] +/- lifting, ESD, EFTR, endoscopic intermuscular dissection, etc.), piecemeal or en bloc, as well as any relevant gastrointestinal disorders, such as a genetic syndrome or inflammatory bowel disease, as this may influence histologic interpretation [74].

Knowledge of the type of procedure may affect specimen handling and pathologic reporting, including the assessment of resection margins. Additional noncore information includes the use of submucosal injection before polypectomy (EMR), the use of electrocautery, and the type of resection (piecemeal or en bloc). En bloc resection allows adequate evaluation of the resection margins in both the horizontal and vertical planes, whereas piecemeal resection precludes a reliable histologic assessment of the completeness of excision.

11 Conclusions

In 2024, polypectomy and colonic tissue resection is based on a selective resection algorithm determined by lesion size, location, morphology, surface pattern, and the estimated risk of SMIC. Moreover, the approach is individualized to account for the individual patient's needs and co-morbidity.

CSP is the primary means by which small polyps and SSLs of all sizes are removed. A wealth of evidence continues to strengthen EMR as the mainstay of LNPCP management in the colon; it is extremely safe and effective. The routine incorporation of margin thermal ablation with STSC has driven recurrence rates at 6-month surveillance to low single-digit figures. Recurrence is readily managed at follow-up. It is not appropriate to choose a more expensive, hazardous, or resource-intensive technique to achieve the same clinical outcome. Modifications of the EMR technique, such as UEMR, offer promise for improving outcomes in niche areas.

Large rectal lesions require special consideration owing to their nearly three-fold greater risk of SMIC in comparison to those in the colon, with the SMIC being covert and not expressed on the lesion surface in approximately 50% of cases. Therefore, a low threshold for en bloc resection by ESD is logical for those lesions with significant nodular components. All large rectal lesions should be managed in specialized centers that offer the full range of tissue resection options, including EMR, ESD, and endoscopic intermuscular dissection.

Teamwork is critical to optimize therapeutic outcomes. This applies to all aspects of the patient journey, including triage, scheduling, device selection, solution preparation, snare and specimen handling, post-procedural recovery, and follow-up. During routine polypectomy practice, every effort should be made to reduce the number of devices used and make the endoscopy "green" and cost-effective. It is also essential to address the ergonomic aspects of endoscopy to ensure safe and effective endoscopic technique, optimal room set-up and screen and bed position, and to minimize the potential for repetitive strain injury, thereby helping to extend career longevity [177].

There is an urgent need for research on sustainable practice in endoscopy to minimize the substantial use of healthcare system resources worldwide. Mitigating endoscopy's carbon footprint can be achieved by following guidelines and the evidence supporting those recommendations [178]. Recent guidelines are expected to reduce surveillance colonoscopies by over 80%, with significant cost-savings and capacity improvements [179]. In summary, a safe, resource-efficient, and complete

polypectomy is the key to the success of CRC screening programs.

Disclaimer

The legal disclaimer for ESGE guidelines [180] applies to this guideline.

Acknowledgments

The authors wish to thank Dr. David Tate, University Hospital of Gent for his critical review and appraisal of this Guideline, along with the many member societies who also sent helpful comments.

Competing interests

R. Bisschops has been on the advisory boards of Pentax, Medtronic, Fujifilm, Cook, Boston Scientific, and Olympus, and has received speaker's fees from Pentax, Medtronic, and Fujifilm; his department has received research grants, and organizational support for events from Pentax and Medtronic, and further organizational support for events from Erbe, Ovesco, and Olympus (all within the last 3 years). M.J. Bourke has received research support from Cook Medical and Olympus (2014 to date). E. Dekker has provided consultancy to Olympus and GI supply (several occasions in recent years). M. Dinis-Ribeiro has provided consultancy to Medtronic and Roche (2021 to 2022) and received a research grant from Fujifilm (2021 to 2022). H. Messmann has provided consultancy to Ambu, Boston Scientific, and Olympus (2022 to date); his department has received research support from Olympus and Satisfai (2022 to date). L. Moons has provided consultancy to Boston Scientific and Pentax (2024 to date) and is a member of the Colorectal cancer guideline committee and chair of the Dutch Guideline group on polypectomy in the rectum and colon. M. Pellisé has provided consultancy to Norgine Iberia (2015 to 2019), GI supply (2019), Fujifilm Europe (2021 to date), and Olympus (2022 to date), and received research support from Fujifilm Spain (2019), Fujifilm Europe (2020 to 2021), Casen recordati (2020), and ZuiZ (2021); her department has also received equipment on loan from Fujifilm Europe (2019 to date); she was on the *Endoscopy* editorial board (2015 to 2021), was ESGE Equity and diversity working group chair (2021 to 2022), councillor for SEED (2016 to 2022), and is president of AEG (2022 to date). G. Rahmi has provided consultancy to Fujifilm and Medtronic (2023 to date). A. Repici has received consultancy fees and research funding from ERBE (2020 to date) and Fujifilm (2018 to date), and speaker's and consultancy fees, and research funding from Boston Scientific (2019 to date). M. Rutter is a member of the British Society of Gastroenterology and is the current Chair of the Joint Advisory Group for Gastrointestinal Endoscopy. Y. Takeuchi has provided consultancy to Boston Scientific Japan (2012 to 2022) and has received speaker's fees from Olympus, Daiichi-Sankyo, Miyarisan Pharmaceutical, Asuka Pharmaceutical, AstraZeneca, EA Pharma, Zeria Pharmaceutical, Fujifilm, Kaneka Medix, Kyorin Pharmaceutical, and the Japan Gastroenterological Endoscopy Society. H. Uchima Koecklin has received proctorship and speaker's fees from ERBE Spain and Olympus Iberia (2022 to 2023). E. Albeniz, A. Amato, H. Awadie, P. Bhandari, M. Ferlitsch, I. Gralnek, C. Hassan R. Jover, D. Libanio, V. Lorenzo-Zuniga, A. Moss, G. Paopatis, A. Probst, M. Risio, L.-M. Rockenbauer, K. Triantafyllou, A. Vosios, and E. Waldmann declare that they have no conflict of interest.

References

- [1] Bretthauer M, Loberg M, Wieszczy P et al. Effect of colonoscopy screening on risks of colorectal cancer and related death. *NEJM* 2022; 387: 1547–1556
- [2] Ferlitsch M, Moss A, Hassan C et al. Colorectal polypectomy and endoscopic mucosal resection (EMR): European Society of Gastrointestinal Endoscopy (ESGE) Clinical Guideline. *Endoscopy* 2017; 49: 270–297
- [3] Bianco MA, Cipolletta L, Rotondano G et al. Prevalence of nonpolypoid colorectal neoplasia: an Italian multicenter observational study. *Endoscopy* 2010; 42: 279–285
- [4] Burgess NG, Hourigan LF, Zanati SA et al. Risk stratification for covert invasive cancer among patients referred for colonic endoscopic mucosal resection: a large multicenter cohort. *Gastroenterology* 2017; 153: 732–742.e1
- [5] van Doorn SC, Hazewinkel Y, East JE et al. Polyp morphology: an interobserver evaluation for the Paris classification among international experts. *Am J Gastroenterol* 2015; 110: 180–187
- [6] Cocomazzi F, Gentile M, Perri F et al. Interobserver agreement of the Paris and simplified classifications of superficial colonic lesions: a Western study. *Endosc Int Open* 2021; 9: E388–E394
- [7] Bogie RMM, Veldman MHJ, Snijders L et al. Endoscopic subtypes of colorectal laterally spreading tumors (LSTs) and the risk of submucosal invasion: a meta-analysis. *Endoscopy* 2018; 50: 263–282
- [8] D'Amico F, Amato A, Iannone A et al. Risk of covert submucosal cancer in patients with granular mixed laterally spreading tumors. *Clin Gastroenterol Hepatol* 2021; 19: 1395–1401
- [9] Bisschops R, East JE, Hassan C et al. Advanced imaging for detection and differentiation of colorectal neoplasia: European Society of Gastrointestinal Endoscopy (ESGE) Guideline – Update 2019. *Endoscopy* 2019; 51: 1155–1179
- [10] Sidhu M, Shahidi N, Vosko S et al. Incremental benefit of dye-based chromoendoscopy to predict the risk of submucosal invasive cancer in large nonpedunculated colorectal polyps. *Gastrointest Endosc* 2022; 95: 527–534.e2
- [11] IJsspeert JE, Bastiaansen BA, van Leerdam ME et al. Development and validation of the WASP classification system for optical diagnosis of adenomas, hyperplastic polyps and sessile serrated adenomas/polyps. *Gut* 2016; 65: 963–970
- [12] Hazewinkel Y, López-Cerón M, East JE et al. Endoscopic features of sessile serrated adenomas: validation by international experts using high-resolution white-light endoscopy and narrow-band imaging. *Gastrointest Endosc* 2013; 77: 916–924
- [13] Dekker E, Houwen B, Puig I et al. Curriculum for optical diagnosis training in Europe: European Society of Gastrointestinal Endoscopy (ESGE) Position Statement. *Endoscopy* 2020; 52: 899–923
- [14] Shahidi N, Vosko S, van Hattem WA et al. Optical evaluation: the crux for effective management of colorectal neoplasia. *Therap Adv Gastroenterol* 2020; 13: 1756284820922746
- [15] Yamada M, Saito Y, Sakamoto T et al. Endoscopic predictors of deep submucosal invasion in colorectal laterally spreading tumors. *Endoscopy* 2016; 48: 456–464
- [16] Shahidi N, Vosko S, Gupta S et al. A rectum-specific selective resection algorithm optimizes oncologic outcomes for large nonpedunculated rectal polyps. *Clin Gastroenterol Hepatol* 2023; 21: 72–80.e2
- [17] Ma MX, Tate DJ, Sidhu M et al. Effect of pre-resection biopsy on detection of advanced dysplasia in large nonpedunculated colorectal polyps undergoing endoscopic mucosal resection. *Endoscopy* 2023; 55: 267–273

- [18] Houwen B, Hassan C, Coupé VMH et al. Definition of competence standards for optical diagnosis of diminutive colorectal polyps: European Society of Gastrointestinal Endoscopy (ESGE) Position Statement. *Endoscopy* 2022; 54: 88–99
- [19] Abu Dayyeh BK, Thosani N, Konda V et al. ASGE Technology Committee systematic review and meta-analysis assessing the ASGE PIVI thresholds for adopting real-time endoscopic assessment of the histology of diminutive colorectal polyps. *Gastrointest Endosc* 2015; 81: 502.e1–e16
- [20] Zachariah R, Samarasena J, Luba D et al. Prediction of polyp pathology using convolutional neural networks achieves "resect and discard" thresholds. *Am J Gastroenterol* 2020; 115: 138–144
- [21] Bourke MJ. Top tips for cold snare polypectomy (with video). *Gastrointest Endosc* 2022; 95: 1226–1232
- [22] Nagl S, Ebigbo A, Goelder SK et al. Underwater vs conventional endoscopic mucosal resection of large sessile or flat colorectal polyps: a prospective randomized controlled trial. *Gastroenterology* 2021; 161: 1460–1474.e1
- [23] Moss A, Bourke MJ, Williams SJ et al. Endoscopic mucosal resection outcomes and prediction of submucosal cancer from advanced colonic mucosal neoplasia. *Gastroenterology* 2011; 140: 1909–1918
- [24] Moss A, Williams SJ, Hourigan LF et al. Long-term adenoma recurrence following wide-field endoscopic mucosal resection (WF-EMR) for advanced colonic mucosal neoplasia is infrequent: results and risk factors in 1000 cases from the Australian Colonic EMR (ACE) study. *Gut* 2015; 64: 57–65
- [25] Belderbos TD, Leenders M, Moons LM et al. Local recurrence after endoscopic mucosal resection of nonpedunculated colorectal lesions: systematic review and meta-analysis. *Endoscopy* 2014; 46: 388–402
- [26] Klein A, Tate DJ, Jayasekaran V et al. Thermal ablation of mucosal defect margins reduces adenoma recurrence after colonic endoscopic mucosal resection. *Gastroenterology* 2019; 156: 604–613.e3
- [27] Sidhu M, Shahidi N, Gupta S et al. Outcomes of thermal ablation of the mucosal defect margin after endoscopic mucosal resection: a prospective, international, multicenter trial of 1000 large nonpedunculated colorectal polyps. *Gastroenterology* 2021; 161: 163–170.e3
- [28] Jayanna M, Burgess NG, Singh R et al. Cost analysis of endoscopic mucosal resection vs surgery for large laterally spreading colorectal lesions. *Clin Gastroenterol Hepatol* 2016; 14: 271–278.e1–e2
- [29] Cronin O, Sidhu M, Shahidi N et al. Comparison of the morphology and histopathology of large nonpedunculated colorectal polyps in the rectum and colon: implications for endoscopic treatment. *Gastrointest Endosc* 2022; 96: 118–124
- [30] Pimentel-Nunes P, Libânio D, Bastiaansen BAJ et al. Endoscopic submucosal dissection for superficial gastrointestinal lesions: European Society of Gastrointestinal Endoscopy (ESGE) Guideline – Update 2022. *Endoscopy* 2022; 54: 591–622
- [31] Tagawa T, Yamada M, Minagawa T et al. Endoscopic characteristics influencing postpolypectomy bleeding in 1147 consecutive pedunculated colonic polyps: a multicenter retrospective study. *Gastrointest Endosc* 2021; 94: 803–811.e6
- [32] Kim HS, Kim TI, Kim WH et al. Risk factors for immediate postpolypectomy bleeding of the colon: a multicenter study. *Am J Gastroenterol* 2006; 101: 1333–1341
- [33] Soh JS, Seo M, Kim KJ. Prophylactic clip application for large pedunculated polyps before snare polypectomy may decrease immediate postpolypectomy bleeding. *BMC Gastroenterol* 2020; 20: 68
- [34] Gweon TG, Lee KM, Lee SW et al. Effect of prophylactic clip application for the prevention of postpolypectomy bleeding of large pedunculated colonic polyps: a randomized controlled trial. *Gastrointest Endosc* 2021; 94: 148–154
- [35] Arimoto J, Chiba H, Ashikari K et al. Safety and efficacy of cold snare polypectomy for pedunculated (Ip) polyps measuring less than 10 mm in diameter. *Int J Colorectal Dis* 2020; 35: 859–867
- [36] Arimoto J, Chiba H, Ashikari K et al. Management of less than 10-mm-sized pedunculated (Ip) polyps with thin stalk: hot snare polypectomy versus cold snare polypectomy. *Dig Dis Sci* 2021; 66: 2353–2361
- [37] Arimoto J, Chiba H, Tachikawa J et al. Evaluation of cold snare polypectomy for small pedunculated (Ip) polyps with thin stalks: a prospective clinical feasibility study. *Scand J Gastroenterol* 2022; 57: 253–259
- [38] Chiba H, Tachikawa J, Arimoto J et al. Endoscopic submucosal dissection of large pedunculated polyps with wide stalks: a retrospective multicenter study. *Endoscopy* 2021; 53: 77–80
- [39] Srinivasan S, Siersema PD, Desai M. Is jumbo biopsy forceps comparable to cold snare for diminutive colorectal polyps? a meta-analysis *Endosc Int Open* 2021; 9: E9–E13
- [40] Huh CW, Kim JS, Choi HH et al. Jumbo biopsy forceps versus cold snares for removing diminutive colorectal polyps: a prospective randomized controlled trial. *Gastrointest Endosc* 2019; 90: 105–111
- [41] Desai S, Gupta S, Copur-Dahi N et al. A prospective randomized study comparing jumbo biopsy forceps to cold snare for the resection of diminutive colorectal polyps. *Surg Endosc* 2020; 34: 1206–1213
- [42] Perrod G, Perez-Cuadrado-Robles E, Coron E et al. Comparison of cold biopsy forceps vs cold snare for diminutive colorectal polyp removal: A multicenter non-inferiority randomized controlled trial. *Clin Res Hepatol Gastroenterol* 2022; 46: 101867
- [43] Wei MT, Louie CY, Chen Y et al. Randomized controlled trial investigating cold snare and forceps polypectomy among small polyps in rates of complete resection: The TINYPOLYP Trial. *Am J Gastroenterol* 2022; 117: 1305–1310
- [44] Kuwai T, Yamada T, Toyokawa T et al. Local recurrence of diminutive colorectal polyps after cold forceps polypectomy with jumbo forceps followed by magnified narrow-band imaging: a multicenter prospective study. *Endoscopy* 2019; 51: 253–260
- [45] Komeda Y, Kashida H, Sakurai T et al. Removal of diminutive colorectal polyps: A prospective randomized clinical trial between cold snare polypectomy and hot forceps biopsy. *World J Gastroenterol* 2017; 23: 328–335
- [46] Shinozaki S, Kobayashi Y, Hayashi Y et al. Efficacy and safety of cold versus hot snare polypectomy for resecting small colorectal polyps: Systematic review and meta-analysis. *Dig Endosc* 2018; 30: 592–599
- [47] Zhang Q, Gao P, Han B et al. Polypectomy for complete endoscopic resection of small colorectal polyps. *Gastrointest Endosc* 2018; 87: 733–740
- [48] Pedersen IB, Rawa-Golebiewska A, Calderwood AH et al. Complete polyp resection with cold snare versus hot snare polypectomy for polyps of 4–9 mm: a randomized controlled trial. *Endoscopy* 2022; 54: 961–969
- [49] de Benito Sanz M, Hernández L, García Martínez MI et al. Efficacy and safety of cold versus hot snare polypectomy for small (5–9 mm) colorectal polyps: a multicenter randomized controlled trial. *Endoscopy* 2022; 54: 35–44
- [50] Papastergiou V, Paraskeva KD, Fragaki M et al. Cold versus hot endoscopic mucosal resection for nonpedunculated colorectal polyps sized 6–10 mm: a randomized trial. *Endoscopy* 2018; 50: 403–411
- [51] Ito T, Takahashi K, Tanabe H et al. Safety and efficacy of cold snare polypectomy for small colorectal polyps: A prospective randomized control trial and one-year follow-up study. *Medicine (Baltimore)* 2021; 100: e26296

- [52] Kim SJ, Lee BI, Jung ES et al. Hot snare polypectomy versus endoscopic mucosal resection for small colorectal polyps: a randomized controlled trial. *Surg Endosc* 2021; 35: 5096–5103
- [53] Chang LC, Chang CY, Chen CY et al. Cold versus hot snare polypectomy for small colorectal polyps: a pragmatic randomized controlled trial. *Ann Intern Med* 2023; 176: 311–319
- [54] Takamaru H, Saito Y, Hammoud GM et al. Comparison of postpolypectomy bleeding events between cold snare polypectomy and hot snare polypectomy for small colorectal lesions: a large-scale propensity score-matched analysis. *Gastrointest Endosc* 2022; 95: 982–989.e6
- [55] Sidhu M, Forbes N, Tate DJ et al. A randomized controlled trial of cold snare polypectomy technique: technique matters more than snare wire diameter. *Am J Gastroenterol* 2022; 117: 100
- [56] Pohl H, Srivastava A, Bensen SP et al. Incomplete polyp resection during colonoscopy—results of the complete adenoma resection (CARE) study. *Gastroenterology* 2013; 144: 74–80.e1
- [57] Moss A, Bourke MJ, Kwan V et al. Succinylated gelatin substantially increases en bloc resection size in colonic EMR: a randomized, blinded trial in a porcine model. *Gastrointest Endosc* 2010; 71: 589–595
- [58] Yamashina T, Uedo N, Akasaka T et al. Comparison of underwater vs conventional endoscopic mucosal resection of intermediate-size colorectal polyps. *Gastroenterology* 2019; 157: 451–461.e2
- [59] Gessl I, Waldmann E, Penz D et al. Resection rates and safety profile of cold vs. hot snare polypectomy in polyps sized 5–10 mm and 11–20 mm. *Dig Liver Dis* 2019; 51: 536–541
- [60] Piraka C, Saeed A, Waljee AK et al. Cold snare polypectomy for non-pedunculated colon polyps greater than 1 cm. *Endosc Int Open* 2017; 5: E184–E189
- [61] Tate DJ, Awadie H, Bahin FF et al. Wide-field piecemeal cold snare polypectomy of large sessile serrated polyps without a submucosal injection is safe. *Endoscopy* 2018; 50: 248–252
- [62] Thoguluva Chandrasekar V, Spadaccini M, Aziz M et al. Cold snare endoscopic resection of nonpedunculated colorectal polyps larger than 10 mm: a systematic review and pooled-analysis. *Gastrointest Endosc* 2019; 89: 929–936.e3
- [63] Tutticci NJ, Hewett DG. Cold EMR of large sessile serrated polyps at colonoscopy (with video). *Gastrointest Endosc* 2018; 87: 837–842
- [64] Uraoka T, Takizawa K, Tanaka S et al. Guidelines for colorectal cold polypectomy (supplement to "Guidelines for colorectal endoscopic submucosal dissection/endoscopic mucosal resection"). *Dig Endosc* 2022; 34: 668–675
- [65] Ket SN, Mangira D, Ng A et al. Complications of cold versus hot snare polypectomy of 10–20 mm polyps: A retrospective cohort study. *JGH Open* 2020; 4: 172–177
- [66] Rex DK, Anderson JC, Pohl H et al. Cold versus hot snare resection with or without submucosal injection of 6- to 15-mm colorectal polyps: a randomized controlled trial. *Gastrointest Endosc* 2022; 96: 330–338
- [67] van Hattem WA, Shahidi N, Vosko S et al. Piecemeal cold snare polypectomy versus conventional endoscopic mucosal resection for large sessile serrated lesions: a retrospective comparison across two successive periods. *Gut* 2021; 70: 1691–1697
- [68] Yoshida N, Inoue K, Tomita Y et al. Cold snare polypectomy for large sessile serrated lesions is safe but follow-up is needed: a single-centre retrospective study. *United European Gastroenterol J* 2021; 9: 370–377
- [69] Mangira D, Raftopoulos S, Hartley I et al. Cold snare polypectomy (CSP)/cold EMR (C-EMR) for medium-sized (10–19mm) sessile colonic polyps: a prospective multicentre study. *Endoscopy* 2022; 54: (Suppl. 01): 262
- [70] Mangira D, Raftopoulos S, Vogrin S et al. Effectiveness and safety of cold snare polypectomy and cold endoscopic mucosal resection for nonpedunculated colorectal polyps of 10–19mm: a multicenter observational cohort study. *Endoscopy* 2023; 55: 627–635
- [71] Suzuki S, Gotoda T, Kusano C et al. Width and depth of resection for small colorectal polyps: hot versus cold snare polypectomy. *Gastrointest Endosc* 2018; 87: 1095–1103
- [72] Barros RA, Monteverde MJ, Dumonceau JM et al. Cold snare polypectomy without submucosal injection: safety and efficacy in 615 large serrated lesions. *Endosc Int Open* 2021; 9: E1421–E1426
- [73] Shimodate Y, Itakura J, Takayama H et al. Impact of submucosal saline solution injection for cold snare polypectomy of small colorectal polyps: a randomized controlled study. *Gastrointest Endosc* 2020; 92: 715–722.e1
- [74] Tate DJ, Argenziano ME, Anderson J et al. Curriculum for training in endoscopic mucosal resection in the colon: European Society of Gastrointestinal Endoscopy (ESGE) Position Statement. *Endoscopy* 2023; 55: 645–679
- [75] Abu Arisha M, Scapa E, Wishahi E et al. Impact of margin ablation after EMR of large nonpedunculated colonic polyps in routine clinical practice. *Gastrointest Endosc* 2023; 97: 559–567
- [76] Burgess NG, Metz AJ, Williams SJ et al. Risk factors for intra-procedural and clinically significant delayed bleeding after wide-field endoscopic mucosal resection of large colonic lesions. *Clin Gastroenterol Hepatol* 2014; 12: 651–661.e1–e3
- [77] Burgess NG, Bassan MS, McLeod D et al. Deep mural injury and perforation after colonic endoscopic mucosal resection: a new classification and analysis of risk factors. *Gut* 2017; 66: 1779–1789
- [78] Bar-Yishay I, Shahidi N, Gupta S et al. Outcomes of deep mural injury after endoscopic resection: an international cohort of 3717 large non-pedunculated colorectal polyps. *Clin Gastroenterol Hepatol* 2022; 20: e139–e147
- [79] Rodríguez Sánchez J, Alvarez-Gonzalez MA, Pellisé M et al. Underwater versus conventional EMR of large nonpedunculated colorectal lesions: a multicenter randomized controlled trial. *Gastrointest Endosc* 2023; 97: 941–951.e2
- [80] Yen AW, Leung JW, Wilson MD et al. Underwater versus conventional endoscopic resection of nondiminutive nonpedunculated colorectal lesions: a prospective randomized controlled trial (with video). *Gastrointest Endosc* 2020; 91: 643–654.e2
- [81] Lenz L, Martins B, Andrade de Paulo G et al. Underwater versus conventional EMR for nonpedunculated colorectal lesions: a randomized clinical trial. *Gastrointest Endosc* 2023; 97: 549–558
- [82] Chandan S, Khan SR, Kumar A et al. Efficacy and histologic accuracy of underwater versus conventional endoscopic mucosal resection for large (>20 mm) colorectal polyps: a comparative review and meta-analysis. *Gastrointest Endosc* 2021; 94: 471–482.e9
- [83] Tziatzios G, Gkolfakis P, Triantafyllou K et al. Higher rate of en bloc resection with underwater than conventional endoscopic mucosal resection: A meta-analysis. *Dig Liver Dis* 2021; 53: 958–964
- [84] Choi AY, Moosvi Z, Shah S et al. Underwater versus conventional EMR for colorectal polyps: systematic review and meta-analysis. *Gastrointest Endosc* 2021; 93: 378–389
- [85] Garg R, Singh A, Mohan BP et al. Underwater versus conventional endoscopic mucosal resection for colorectal lesions: a systematic review and meta-analysis. *Endosc Int Open* 2020; 8: E1884–E1894
- [86] Ni DQ, Lu YP, Liu XQ et al. Underwater vs conventional endoscopic mucosal resection in treatment of colorectal polyps: A meta-analysis. *World J Clin Cases* 2020; 8: 4826–4837
- [87] Tan DJH, Ng CH, Lim XC et al. Is underwater endoscopic mucosal resection of colon polyps superior to conventional techniques? A network analysis of endoscopic mucosal resection and submucosal dissection *Endosc Int Open* 2022; 10: E154–E162

- [88] Yamashina T, Hanaoka N, Setoyama T et al. Efficacy of underwater endoscopic mucosal resection for nonpedunculated colorectal polyps: a systematic review and meta-analysis. *Cureus* 2021; 13: e17261
- [89] Ohata K, Kobayashi N, Sakai E et al. Long-term outcomes after endoscopic submucosal dissection for large colorectal epithelial neoplasms: a prospective, multicenter, cohort trial from Japan. *Gastroenterology* 2022; 163: 1423–1434.e2
- [90] Jacques J, Schaefer M, Wallenhorst T et al. Endoscopic en bloc versus piecemeal resection of large nonpedunculated colonic adenomas: a randomized comparative trial. *Ann Intern Med* 2024; 177: 29–38
- [91] Burgess NG, Bourke MJ. Endoscopic submucosal dissection versus endoscopic mucosal resection of large colon polyps: use both for the best outcomes. *Ann Int Med* 2024; 177: 89–90
- [92] Bahin FF, Heitman SJ, Rasouli KN et al. Wide-field endoscopic mucosal resection versus endoscopic submucosal dissection for laterally spreading colorectal lesions: a cost-effectiveness analysis. *Gut* 2018; 67: 1965–1973
- [93] Tate DJ, Bahin FF, Desomer L et al. Cold-forceps avulsion with adjunct snare-tip soft coagulation (CAST) is an effective and safe strategy for the management of non-lifting large laterally spreading colonic lesions. *Endoscopy* 2018; 50: 52–62
- [94] Kumar V, Broadley H, Rex DK. Safety and efficacy of hot avulsion as an adjunct to EMR (with videos). *Gastrointest Endosc* 2019; 89: 999–1004
- [95] van der Voort VRH, Moons LMG, de Graaf W et al. Efficacy and safety of cap-assisted endoscopic mucosal resection for treatment of non-lifting colorectal polyps. *Endoscopy* 2022; 54: 509–514
- [96] Kimoto Y, Sakai E, Inamoto R et al. Safety and efficacy of cold snare polypectomy without submucosal injection for large sessile serrated lesions: a prospective study. *Clin Gastroenterol Hepatol* 2022; 20: e132–e138
- [97] Mangira D, Cameron K, Simons K et al. Cold snare piecemeal EMR of large sessile colonic polyps ≥ 20 mm (with video). *Gastrointest Endosc* 2020; 91: 1343–1352
- [98] Albéniz E, Álvarez MA, Espinós JC et al. Clip closure after resection of large colorectal lesions with substantial risk of bleeding. *Gastroenterology* 2019; 157: 1213–1221.e4
- [99] Pohl H, Grimm IS, Moyer MT et al. Clip closure prevents bleeding after endoscopic resection of large colon polyps in a randomized trial. *Gastroenterology* 2019; 157: 977–984.e3
- [100] Gupta S, Sidhu M, Shahidi N et al. Effect of prophylactic endoscopic clip placement on clinically significant post-endoscopic mucosal resection bleeding in the right colon: a single-centre, randomised controlled trial. *Lancet Gastroenterol Hepatol* 2022; 7: 152–160
- [101] Bahin FF, Rasouli KN, Williams SJ et al. Prophylactic clipping for the prevention of bleeding following wide-field endoscopic mucosal resection of laterally spreading colorectal lesions: an economic modeling study. *Endoscopy* 2016; 48: 754–761
- [102] Whitfield AM, Burgess NG, Bahin FF et al. Histopathological effects of electro-surgical interventions in an in vivo porcine model of colonic endoscopic mucosal resection. *Gut* 2022; 71: 864–870
- [103] Kemper G, Turan AS, Schoon EJ et al. Endoscopic techniques to reduce recurrence rates after colorectal EMR: systematic review and meta-analysis. *Surg Endosc* 2021; 35: 5422–5429
- [104] Forbes N, Gupta S, Frehlich L et al. Clip closure to prevent adverse events after EMR of proximal large nonpedunculated colorectal polyps: meta-analysis of individual patient data from randomized controlled trials. *Gastrointest Endosc* 2022; 96: 721–731.e2
- [105] Albéniz E, Fraile M, Ibáñez B et al. A scoring system to determine risk of delayed bleeding after endoscopic mucosal resection of large colorectal lesions. *Clin Gastroenterol Hepatol* 2016; 14: 1140–1147
- [106] Albéniz E, Gimeno-García AZ, Fraile M et al. Clinical validation of risk scoring systems to predict risk of delayed bleeding after EMR of large colorectal lesions. *Gastrointest Endosc* 2020; 91: 868–878.e3
- [107] Parikh ND, Zanooco K, Keswani RN et al. A cost-efficacy decision analysis of prophylactic clip placement after endoscopic removal of large polyps. *Clin Gastroenterol Hepatol* 2013; 11: 1319–1324
- [108] Albéniz E, Enguita-Germán M, Gimeno-García AZ et al. The answer to "When to Clip" after colorectal endoscopic mucosal resection based on a cost-effectiveness analysis. *Am J Gastroenterol* 2021; 116: 311–318
- [109] Paspatis GA, Arvanitakis M, Dumonceau JM et al. Diagnosis and management of iatrogenic endoscopic perforations: European Society of Gastrointestinal Endoscopy (ESGE) Position Statement – Update 2020. *Endoscopy* 2020; 52: 792–810
- [110] Arezzo A, Passera R, Marchese N et al. Systematic review and meta-analysis of endoscopic submucosal dissection vs endoscopic mucosal resection for colorectal lesions. *United European Gastroenterol J* 2016; 4: 18–29
- [111] Kothari ST, Huang RJ, Shaikat A et al. ASGE review of adverse events in colonoscopy. *Gastrointest Endosc* 2019; 90: 863–876.e33
- [112] Derbyshire E, Hungin P, Nickerson C et al. Colonoscopic perforations in the English National Health Service Bowel Cancer Screening Programme. *Endoscopy* 2018; 50: 861–870
- [113] Khater S, Rahmi G, Perrod G et al. Over-the-scope clip (OTSC) reduces surgery rate in the management of iatrogenic gastrointestinal perforations. *Endosc Int Open* 2017; 5: E389–E394
- [114] Ma MX, Bourke MJ. Complications of endoscopic polypectomy, endoscopic mucosal resection and endoscopic submucosal dissection in the colon. *Best Pract Res Clin Gastroenterol* 2016; 30: 749–767
- [115] Holt BA, Jayasekaran V, Sonson R et al. Topical submucosal chromoendoscopy defines the level of resection in colonic EMR and may improve procedural safety (with video). *Gastrointest Endosc* 2013; 77: 949–953
- [116] Sidhu M, Tate DJ, Desomer L et al. The size, morphology, site, and access score predicts critical outcomes of endoscopic mucosal resection in the colon. *Endoscopy* 2018; 50: 684–692
- [117] Uno Y, Munakata A. The non-lifting sign of invasive colon cancer. *Gastrointest Endosc* 1994; 40: 485–489
- [118] Kim HG, Thosani N, Banerjee S et al. Effect of prior biopsy sampling, tattoo placement, and snare sampling on endoscopic resection of large nonpedunculated colorectal lesions. *Gastrointest Endosc* 2015; 81: 204–213
- [119] Shahidi N, Vosko S, Gupta S et al. Previously attempted large nonpedunculated colorectal polyps are effectively managed by endoscopic mucosal resection. *Am J Gastroenterol* 2021; 116: 958–966
- [120] Ohmori M, Yamasaki Y, Iwagami H et al. Propensity score-matched analysis of endoscopic resection for recurrent colorectal neoplasms: A pilot study. *J Gastroenterol Hepatol* 2021; 36: 2568–2574
- [121] Schmidt A, Beyna T, Schumacher B et al. Colonoscopic full-thickness resection using an over-the-scope device: a prospective multicentre study in various indications. *Gut* 2018; 67: 1280–1289
- [122] Zwager LW, Bastiaansen BAJ, Bronzwaer MES et al. Endoscopic full-thickness resection (eFTR) of colorectal lesions: results from the Dutch colorectal eFTR registry. *Endoscopy* 2020; 52: 1014–1023
- [123] Meier B, Stritzke B, Kuellmer A et al. Efficacy and safety of endoscopic full-thickness resection in the colorectum: results from the German Colonic FTRD Registry. *Am J Gastroenterol* 2020; 115: 1998–2006
- [124] Zwager LW, Mueller J, Stritzke B et al. Adverse events of endoscopic full-thickness resection: results from the German and Dutch nationwide colorectal FTRD registry. *Gastrointest Endosc* 2023; 97: 780–789.e4

- [125] Faller J, Jacques J, Oung B et al. Endoscopic submucosal dissection with double clip and rubber band traction for residual or locally recurrent colonic lesions after previous endoscopic mucosal resection. *Endoscopy* 2020; 52: 383–388
- [126] Kobayashi R, Hirasawa K, Ikeda R et al. The feasibility of colorectal endoscopic submucosal dissection for the treatment of residual or recurrent tumor localized in therapeutic scar tissue. *Endosc Int Open* 2017; 5: E1242–E1250
- [127] Kandiah K, Subramaniam S, Chedgy F et al. A novel non-thermal resection tool in endoscopic management of scarred polyps. *Endosc Int Open* 2019; 7: E974–E978
- [128] Kaul V, Diehl D, Enslin S et al. Safety and efficacy of a novel powered endoscopic debridement tissue resection device for management of difficult colon and foregut lesions: first multicenter U.S. experience. *Gastrointest Endosc* 2021; 93: 640–646
- [129] Longcroft-Wheaton G, Duku M, Mead R et al. Risk stratification system for evaluation of complex polyps can predict outcomes of endoscopic mucosal resection. *Dis Colon Rectum* 2013; 56: 960–966
- [130] Bronzwaer MES, Koens L, Bemelman WA et al. Volume of surgery for benign colorectal polyps in the last 11 years. *Gastrointest Endosc* 2018; 87: 552–561.e1
- [131] Peery AF, Cools KS, Strassle PD et al. Increasing rates of surgery for patients with nonmalignant colorectal polyps in the United States. *Gastroenterology* 2018; 154: 1352–1360.e3
- [132] Meulen LWT, van der Zander QEW, Bogie RMM et al. Evaluation of polypectomy quality indicators of large nonpedunculated colorectal polyps in a nonexpert, bowel cancer screening cohort. *Gastrointest Endosc* 2021; 94: 1085–1095.e2
- [133] Rodrigues R, Geyl S, Albuys J et al. Effect of implementing a regional referral network on surgical referral rate of benign polyps found during a colorectal cancer screening program: A population-based study. *Clin Res Hepatol Gastroenterol* 2021; 45: 101488
- [134] Ahlenstiel G, Hourigan LF, Brown G et al. Actual endoscopic versus predicted surgical mortality for treatment of advanced mucosal neoplasia of the colon. *Gastrointest Endosc* 2014; 80: 668–676
- [135] Djinbachian R, Iratni R, Durand M et al. Rates of incomplete resection of 1- to 20-mm colorectal polyps: a systematic review and meta-analysis. *Gastroenterology* 2020; 159: 904–914.e12
- [136] Saito Y, Sakamoto T, Dekker E et al. First report from the International Evaluation of Endoscopic classification Japan NBI Expert Team: International multicenter web trial. *Dig Endosc* 2023; doi:10.1111/den.14682
- [137] Kuellmer A, Mueller J, Caca K et al. Endoscopic full-thickness resection for early colorectal cancer. *Gastrointest Endosc* 2019; 89: 1180–1189.e1
- [138] Dolan RD, Bazarbashi AN, McCarty TR et al. Endoscopic full-thickness resection of colorectal lesions: a systematic review and meta-analysis. *Gastrointest Endosc* 2022; 95: 216–224.e18
- [139] Acuna SA, Elmi M, Shah PS et al. Preoperative localization of colorectal cancer: a systematic review and meta-analysis. *Surg Endosc* 2017; 31: 2366–2379
- [140] Wang R, Zhan HL, Li DZ et al. Application of endoscopic tattooing with carbon nanoparticlet in the treatment for advanced colorectal cancer. *Zhonghua Wei Chang Wai Ke Za Zhi* 2020; 23: 56–64
- [141] Hershorn O, Park J, Singh H et al. Rates and predictors of repeat preoperative endoscopy for elective colorectal resections: how can we avoid repeated procedures? *Surg Endosc* 2022; 36: 4115–4123
- [142] Rodríguez de Santiago E, Dinis-Ribeiro M, Pohl H et al. Reducing the environmental footprint of gastrointestinal endoscopy: European Society of Gastrointestinal Endoscopy (ESGE) and European Society of Gastroenterology and Endoscopy Nurses and Associates (ES-GENA) Position Statement. *Endoscopy* 2022; 54: 797–826
- [143] Shahidi N, Gupta S, Whitfield A et al. Simple optical evaluation criteria reliably identify the post-endoscopic mucosal resection scar for benign large non-pedunculated colorectal polyps without tattoo placement. *Endoscopy* 2022; 54: 173–177
- [144] Medina-Prado L, Hassan C, Dekker E et al. When and how to use endoscopic tattooing in the colon: an international Delphi agreement. *Clin Gastroenterol Hepatol* 2021; 19: 1038–1050
- [145] Barquero D, González V, García O et al. Ways to perform an endoscopic tattoo. Prospective and randomized study in patients with colorectal neoplasm. *Rev Esp Enferm Dig* 2021; 113: 519–523
- [146] Milone M, Vignali A, Manigrasso M et al. Sterile carbon particle suspension vs India ink for endoscopic tattooing of colonic lesions: a randomized controlled trial. *Tech Coloproctol* 2019; 23: 1073–1078
- [147] Zhang S, Wang Q, Feng Y et al. Clip or tattooing: a comparative study for preoperative colon cancer endoscopic localization. *Front Oncol* 2022; 12: 846900
- [148] Pioche M, Wallenhorst T, Lepetit H et al. Endoscopic mucosal resection with anchoring of the snare tip: multicenter retrospective evaluation of effectiveness and safety. *Endosc Int Open* 2019; 7: E1496–E1502
- [149] Jung Y, Moon JR, Jeon SR et al. Usefulness of narrow-band imaging for the detection of remnant sessile-serrated adenoma (SSA) tissue after endoscopic resection: the KASID multicenter study. *Surg Endosc* 2021; 35: 5217–5224
- [150] Yoshida N, Fukumoto K, Hasegawa D et al. Recurrence rate and lesions characteristics after cold snare polypectomy of high-grade dysplasia and T1 lesions: A multicenter analysis. *J Gastroenterol Hepatol* 2021; 36: 3337–3344
- [151] Tate DJ, Desomer L, Klein A et al. Adenoma recurrence after piecemeal colonic EMR is predictable: the Sydney EMR recurrence tool. *Gastrointest Endosc* 2017; 85: 647–656.e6
- [152] Rashid MU, Khetpal N, Zafar H et al. Colon mucosal neoplasia referred for endoscopic mucosal resection: Recurrence of adenomas and prediction of submucosal invasion. *World J Gastrointest Endosc* 2020; 12: 198–211
- [153] Mehta N, Abushahin A, Sadaps M et al. Recurrence with malignancy after endoscopic resection of large colon polyps with high-grade dysplasia: incidence and risk factors. *Surg Endosc* 2021; 35: 2500–2508
- [154] Song EM, Yang HJ, Lee HJ et al. Endoscopic resection of cecal polyps involving the appendiceal orifice: a KASID multicenter study. *Dig Dis Sci* 2017; 62: 3138–3148
- [155] Emmanuel A, Williams S, Gulati S et al. Incidence of microscopic residual adenoma after complete wide-field endoscopic resection of large colorectal lesions: evidence for a mechanism of recurrence. *Gastrointest Endosc* 2021; 94: 368–375
- [156] Komeda Y, Watanabe T, Sakurai T et al. Risk factors for local recurrence and appropriate surveillance interval after endoscopic resection. *World J Gastroenterol* 2019; 25: 1502–1512
- [157] Alexandrino G, Figueiredo ML, Domingues TD et al. The risk of residual or recurring adenoma after piecemeal endoscopic mucosal resection of large non-pedunculated colorectal polyps is predictable. *Eur J Gastroenterol Hepatol* 2020; 32: 713–717
- [158] Barosa R, Mohammed N, Rembacken B. Risk stratification of colorectal polyps for predicting residual or recurring adenoma using the Size/Morphology/Site/Access score. *United European Gastroenterol J* 2018; 6: 630–638
- [159] Burgess NG, Bourke MJ. Can we stop routine biopsy of post-endoscopic mucosal resection scars? *Endoscopy* 2023; 55: 608–610
- [160] Rahmi G, Tanaka S, Ohara Y et al. Efficacy of endoscopic submucosal dissection for residual or recurrent superficial colorectal tumors after endoscopic mucosal resection. *J Dig Dis* 2015; 16: 14–21

- [161] Ichkhanian Y, Vosoughi K, Diehl DL et al. A large multicenter cohort on the use of full-thickness resection device for difficult colonic lesions. *Surg Endosc* 2021; 35: 1296–1306
- [162] Tate DJ, Desomer L, Argenziano ME et al. Treatment of adenoma recurrence after endoscopic mucosal resection. *Gut* 2023; 72: 1875–1886
- [163] Burgess NG, Bahin FF, Bourke MJ. Colonic polypectomy (with videos). *Gastrointest Endosc* 2015; 81: 813–835
- [164] Klein A, Bourke MJ. Advanced polypectomy and resection techniques. *Gastrointest Endosc Clin N Am* 2015; 25: 303–333
- [165] Fahrtash-Bahin F, Holt BA, Jayasekeran V et al. Snare tip soft coagulation achieves effective and safe endoscopic hemostasis during wide-field endoscopic resection of large colonic lesions (with videos). *Gastrointest Endosc* 2013; 78: 158–163.e1
- [166] Albéniz E, Montori S, Rodríguez de Santiago E et al. Preventing postendoscopic mucosal resection bleeding of large nonpedunculated colorectal lesions. *Am J Gastroenterol* 2022; 117: 1080–1088
- [167] Triantafyllou K, Gkolfakis P, Gralnek IM et al. Diagnosis and management of acute lower gastrointestinal bleeding: European Society of Gastrointestinal Endoscopy (ESGE) Guideline. *Endoscopy* 2021; 53: 850–868
- [168] Sengupta N, Feuerstein JD, Jairath V et al. Management of patients with acute lower gastrointestinal bleeding: an updated ACG Guideline. *Am J Gastroenterol* 2023; 118: 208–231
- [169] Rodríguez de Santiago E, Hernández-Tejero M, Rivero-Sánchez L et al. Management and outcomes of bleeding within 30 days of colonic polypectomy in a large, real-life, multicenter cohort study. *Clin Gastroenterol Hepatol* 2021; 19: 732–742.e6
- [170] Metz AJ, Bourke MJ, Moss A et al. Factors that predict bleeding following endoscopic mucosal resection of large colonic lesions. *Endoscopy* 2011; 43: 506–511
- [171] Slivka A, Parsons WG, Carr-Locke DL. Endoscopic band ligation for treatment of post-polypectomy hemorrhage. *Gastrointest Endosc* 1994; 40: 230–232
- [172] Bugajski M, Wieszczy P, Pisera M et al. Effectiveness of digital feedback on patient experience and 30-day complications after screening colonoscopy: a randomized health services study. *Endosc Int Open* 2019; 7: E537–E544
- [173] Hoff G, de Lange T, Bretthauer M et al. Patient-reported adverse events after colonoscopy in Norway. *Endoscopy* 2017; 49: 745–753
- [174] Holt BA, Bassan MS, Sexton A et al. Advanced mucosal neoplasia of the anorectal junction: endoscopic resection technique and outcomes (with videos). *Gastrointest Endosc* 2014; 79: 119–126
- [175] Shichijo S, Takeuchi Y, Shimodate Y et al. Performance of perioperative antibiotics against post-endoscopic submucosal dissection coagulation syndrome: a multicenter randomized controlled trial. *Gastrointest Endosc* 2022; 95: 349–359
- [176] Kuo E, Wang K, Liu X. A focused review on advances in risk stratification of malignant polyps. *Gastroenterology Res* 2020; 13: 163–183
- [177] Walsh CM, Qayed E, Aihara H et al. Core curriculum for ergonomics in endoscopy. *Gastrointest Endosc* 2021; 93: 1222–1227
- [178] Siau K, Hayee BH, Gayam S. Endoscopy's current carbon footprint. *Techn Innov Gastrointest Endosc* 2021; 23: 344–352
- [179] Shandro B, Chang V, Mathur J et al. Real-life cost savings and capacity improvements on implementation of the new BSG post-polypectomy surveillance guideline. *Clin Med (Lond)* 2020; 20: 116–117
- [180] Hassan C, Ponchon T, Bisschops R et al. European Society of Gastrointestinal Endoscopy (ESGE) Publications Policy – Update 2020. *Endoscopy* 2020; 52: 123–126

Supplementary material

Colorectal polypectomy and endoscopic mucosal resection: European Society of Gastrointestinal Endoscopy (ESGE) Guideline – Update 2024

Monika Ferlitsch, Cesare Hassan, Raf Bisschops, Pradeep Bhandari, Mario Dinis-Ribeiro, Mauro Risio, Gregorios Paspatis, Alan Moss, Diogo Libanio, Vincente Lorenzo-Zuniga, Andrei Voiosu, Matt Rutter, Maria Pellisé, Leon Moons, Andreas Probst, Halim Awadie, Arnaldo Amato, Yoji Takeuchi, Alessandro Repici, Gabriel Rahmi, Hugo Uchima Koecklin, Eduardo Albeniz, Lisa-Maria Rockenbauer, Elisabeth Waldmann, Helmut Messmann, Konstantinos Triantafyllou, Rodrigo Jover, Ian Gralnek, Evelien Dekker, Michael J. Bourke

Appendix 1s Key questions 2022.

General comments:

Note that management of anticoagulations and other medications in the peri-procedural setting is not covered here, because it is covered by other guidelines

This guideline does not address post-polypectomy surveillance questions as these are covered in a separate guidelines

Task Force 1: Key question 1: Polyp definitions, definition of polypectomy, mucosectomy, polypectomy indications, and efficacy (Participants: XY (TF leader), XY)	In charge (TF leader in bold)
	Ferlitsch
a) What is the definition of a polyp? How should polyps be classified (Paris classification)?	Libanio
b) Which polyps should be removed? Do all polyps require retrieval for histology (just mention, PIVI I, PIVI II)?	Libanio
c) Definition of polypectomy, mucosectomy.	Lorenzo Zuniga
d) What are the benefits of polypectomy? (mortality, colorectal cancer prevention, cost benefit)	Rutter

Supplementary material

Task force 2: Key question 2: What is the evidence based approach to polypectomy of different polyp types and sizes. (Participants: XY (TF leader), XY)	In charge (TF leader in bold)
	Raf Bisschops
What is the best approach to achieve safe and complete polypectomy for the following polyps?	
a) Diminutive polyps <=5 mm	Pellisè
b) Small polyps (6-9 mm)	Pellisè
c) Sessile polyps 10-19 mm	Moss
d) Pedunculated lesions according to diameter of stalk and headsize, does a specific cut of exists: (Stalk ≤ 5mm, head ≤ 15-20mm, Pedunculated lesions: Stalk > 5mm, head >15-20mm)	Paspatis
e) Which polyps should be referred to Tertiary center with expertise in complex Colorectal tissue resection for management. What are the defining characteristics of such a center (capable of complex emr and ESD) and ideal minimum annual case load. Which polyps require greater level of support (eg. hospital environment) for removal?	Moons
f) Which polyp characteristics (including size, site, morphology and optical chromo features) require consideration of other (non-snare) techniques e.g. ESD, FTR or surgery. Preremoval criteria (SMSA criteria: size, morphology, site, access)	Probst
g) Which lesions should be tattooed? What is the best technique and location for tattoo placement?	Rutter M

Task force 3: Key question 3: Endoscopic Mucosal Resection (EMR) for Large (≥20mm) Non Pedunculated Colorectal Polyps (LNPCP) evidence for: (Participants: XY (TF leader), XY)	In charge (TF leader in bold)
	Bourke
a) Lesion specific assessment prior to EMR (SMSA and other aspects): when not to proceed.	Bhandari
b) Brief description of the EMR technique – injection technique, snare technique, approach to the lesion(en-bloc/piecemeal, proximal/distal edge first) and snare selection (size and type).	Amato

Supplementary material

c) Role of piece meal cold snare polypectomy	Moss
d) Evidence for underwater polypectomy	Takeuchi
e) Consideration regarding Lesion location? Right vs. left? Need for Rectum specific algorithm?	Bourke
f) Submucosal injection – which solution is best?	Repici
g) Benefits and limits of en bloc resection, when to consider via EMR.	Rahmi
h) Adjunctive ablation e.g. APC or soft coagulation	Pellisè
i) Management of the non-lifting polyp: Avulsion Hot or Cold with STSC (CAST).	Uchima Koecklin
j) Definition of the successful EMR procedure and dealing with incomplete resection	Moons
k) New and alternative techniques of Polypectomy and EMR: Under water. Expanding role of piecemeal cold EMR. Esp for SSP	Albeniz
l) Specimen retrieval and dealing with the specimens for histology (belong in part to Key question 6?)	Waldmann, Risio

Task force 4: Key question 4: Technical equipment. (Participants: XY (TF leader), XY)	In charge (TF leader in bold)
	Bhandari
a) What electrocautery generator for polypectomy is best?	Repici A
b) Benefit of CO2 use	Repici A
c) Which types of snares should be used for different polyps	Bhandari P
d) Team working (snare, needle...)	Triantafyllou

Supplementary material

Task force 5: Key question 5: : Completeness of polypectomy and emr/ Prevention of Polyp recurrence (Participants: XY (TF leader), XY)	In charge (TF leader in bold)
	Dinis-Ribeiro
a) What is the rate of post-polypectomy; hot vs cold and post-EMR recurrence?	Jover
b) What are the predictive factors for recurrence?	Bourke
c) What are the endoscopic techniques to prevent/detect/treat recurrences? After conventional polypectomy and after EMR	Rahmi
d) How can we prove completeness of resection after snare polypectomy or EMR? Is it necessary to prove this, and using what technique?	Albeniz
e) Burden of interval cancer due to incomplete resection: In the context of other causes eg missed lesions. Serrated vs conventional pathway tumours.	Moons

Task force 6: Key question 6: Histological management of the histology specimen. (Participants: XY (TF leader), XY)	In charge (TF leader in bold)
	Risio M
a) How is the histology specimen best managed and reported upon - processing, analysis and reporting. Are there requirements of a histologist managing polypectomy specimens (minimum reporting standards).	Dekker E
b) What histology findings should require further action eg. referral for surgery. Eg. discussion about Haggitt level for pedunculated polyps, lymphovascular invasion, degree of differentiation, superficial submucosal invasion and lymph node involvement risk	Risio MC

Supplementary material

Task force 7: Key question 7: Complications and their management (Participants: XY (TF leader), XY)	In charge (TF leader in bold)
	Paspatis G
a) Adverse events: Early recognition, Risk factors and prevention. How can those risks be mitigated / controlled (prevention of complications).	Gralnek I,
b) Methods to ameliorate frequency and severity of post polypectomy complications (bleeding and perforation): How to assess risk/stratify risk. Which techniques (eg. prophylactic clip).	Gralnek I,
c) Definition of bleeding (major, minor, go to upper GI ESGE guideline), d) Management of immediate, delayed and refractory bleeding	Gralnek I
e) Perforation –Policy and protocols	Paspatis
f) Management of complications: perforation: - immediate and delayed, target sign, risk factors, peritoneal cavity management, diagnosis and endoscopic/surgical treatment.	Paspatis
g) Pain due to other causes (not perforation), post polypectomy syndrome	Paspatis
h) How to audit complication rate?	Waldmann E

Supplementary material

Task force 8: Key question 8: Other issues (Participants: XY (TF leader), XY)	In charge (TF leader in bold)
	Ferlitsch M
a) What are the quality indicators of polypectomy/mucosectomy?	Ferlitsch M
b) What is the training (minimal standards, volume of EMR)?	Bhandari P
c) Do we need tertiary centres? Role of the advanced tissue resection network for advanced colonic lesions.	Bhandari P
d) Research questions	Dekker E